

# Relation between the Persistence of an Abnormal Muscle Response and the Long-Term Clinical Course after Microvascular Decompression for Hemifacial Spasm

Hana TOBISHIMA,<sup>1</sup> Toru HATAYAMA,<sup>2</sup> and Hiroki OHKUMA<sup>1</sup>

<sup>1</sup>Department of Neurosurgery, Hirosaki University School of Medicine, Hirosaki, Aomori;

<sup>2</sup>Department of Neurosurgery, Aomori City Hospital, Aomori, Aomori

## Abstract

Mentalis muscle responses to electrical stimulation of the zygomatic branch of the facial nerve are considered abnormal muscle responses (AMRs) and can be used to monitor the success of decompression in microvascular decompression (MVD) surgery. The aim of this study was to compare the long-term outcome of MVD surgery in which the AMR disappeared to the outcome of surgery in which the AMR persisted. From 2005 to 2009, 131 patients with hemifacial spasm received MVD surgery with intraoperative monitoring of AMR. At 1 week postsurgery, spasms had resolved in 82% of cases in the AMR-disappearance group and 46% of cases in the persistent-AMR group, mild spasms were present in 10% of cases in the AMR-disappearance group and 31% of cases in the persistent-AMR group, and moderate were present spasms in 8% of cases in the AMR-disappearance group and 23% of cases in the persistent-AMR group ( $P < 0.05$ ). At 1 year postsurgery, spasms had resolved in 92% of cases in the AMR-disappearance group and 84% of cases in the persistent-AMR group, mild spasms were present in 6% of cases in the AMR-disappearance group and 8% of cases in the persistent-AMR group, and moderate spasms were present in 3% of cases in the AMR-disappearance group and 8% of the cases in the persistent-AMR group ( $P = 0.56$ ). These results indicate that the long-term outcome of MVD surgery in which the AMR persisted was no different to that of MVD surgery in which the AMR disappeared.

Key words: microvascular decompression, hemifacial spasm, abnormal muscle response, long-term clinical course

## Introduction

Microvascular decompression (MVD) was established as a method of treating hemifacial spasm by Jannetta et al.,<sup>1</sup> and results in resolution of spasms in over 90% of cases.<sup>2–7</sup> Intraoperative monitoring of an abnormal muscle response (AMR) to electrical stimulation of the facial nerve has been used to improve the outcome of treatment.<sup>4,7–13</sup> The AMR is recorded from facial muscles that are innervated by one branch of the facial nerve while a different branch of the facial nerve is electrically stimulated. It is presumed that the response is due to cross-transmission of the antidromic activity in the branch of the facial nerve that is stimulated.<sup>14</sup> The AMR can be recorded intraoperatively in most hemifacial spasm patients and, in most cases, it

disappears within seconds after the vessel that is causing compression is removed from the facial nerve.<sup>14–16</sup> Therefore, intraoperative monitoring of the AMR can help to better localize the exact site of the contact between vessel and nerve, and improves the results of the decompression procedure.<sup>3,4,7–13,17,18</sup>

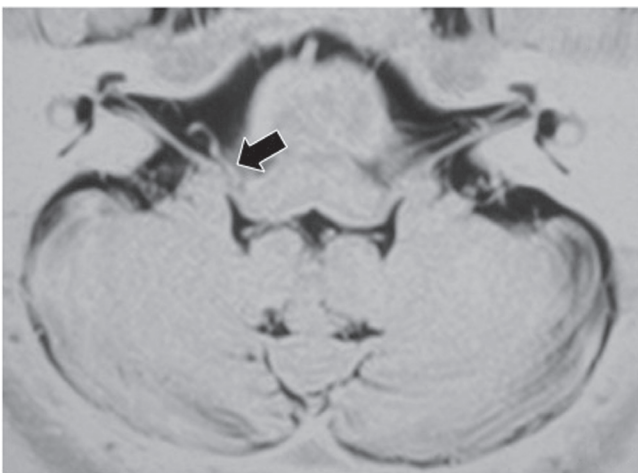
In some patients, however, the AMR does not disappear after decompression. When that happens, there is concern that the symptoms will not be cured postoperatively; however, this is not always the case and, in some patients, the spasms do gradually disappear.<sup>3,18</sup> However, the reported frequency of such cases varies because the methods of evaluation and evaluation periods are not standardized across studies.<sup>3,4,7,10,12,13,18</sup> The aim of this retrospective study was to compare the long-term outcome of decompression surgery in which the AMR persisted to that of decompression surgery in which the AMR disappeared.

## Materials and Methods

One hundred and forty-five patients underwent MVD for hemifacial spasm from January 2005 to December 2009 at Aomori City Hospital. Intraoperative AMR was recorded in 131 patients. These patients formed the sample for our study. The ethics committee of our institution approved the study and patients provided informed consent.

Preoperative magnetic resonance images were obtained for all patients, and magnetic resonance cisternography, in which the black and white of the constructive interface in steady state are reversed, was used to determine the presence or absence of compressing blood vessels in the vicinity of the root exit zone (REZ) and the type of any such blood vessels (Fig. 1). The operation was performed under general anesthesia and, after endotracheal intubation, anesthesia was maintained with an intravenous anesthetic without administration of a muscle relaxant. A needle electrode was subcutaneously placed in the zygomatic branch of the facial nerve, and the nerve was electrically stimulated. A normal muscle response was confirmed with a needle electrode inserted into the orbicularis oculi muscle, and AMRs were recorded from a needle electrode inserted into the mentalis muscle (Figs. 2, 3A). The stimulating current was a 0.3 ms pulse wave adjusted to supramaximal strength (5–20 mA), and recordings were made at approximately 5 min intervals until the dura mater was incised, and continuously after the dura mater was incised.

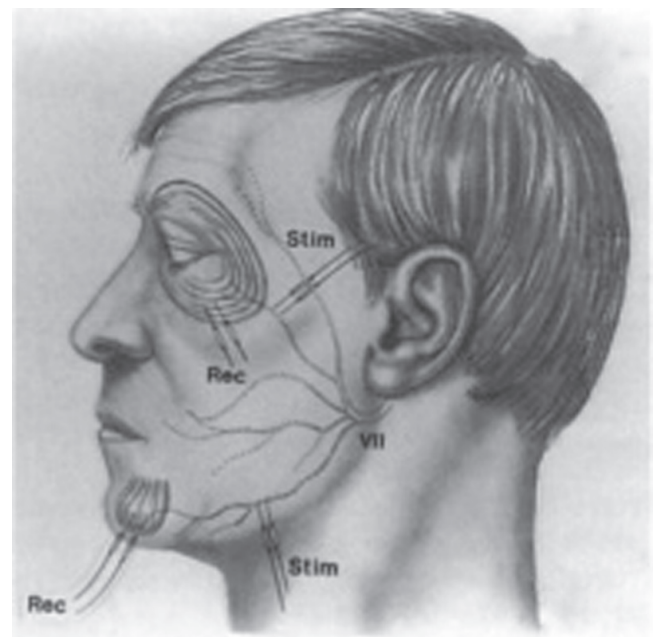
The operation was performed in the contralateral decubitus position. After making a diagonal incision



**Fig. 1** Preoperative magnetic resonance image from a patient with right hemifacial spasm. *Arrow* indicates the posterior inferior cerebellar artery that is compressing the root exit zone of the facial nerve.

approximately 4 cm long inside the hairline posterior to the pinna, a small lateral suboccipital craniotomy was performed below the asterion (Fig. 4A). The dura mater was incised and, after opening the lateral cerebello-medullary cistern, the cerebrospinal fluid was aspirated. The cerebellar flocculus and glossopharyngeal nerve were then separated, and the REZ of the facial nerve was identified. In many cases, the REZ was compressed by the anterior inferior cerebellar artery, the posterior inferior cerebellar artery, or the vertebral artery (Fig. 4B), and the REZ was decompressed by moving the offending blood vessel toward the petrous bone (Fig. 4C) and attaching it to the dura with Teflon in the form of tape and fibrin glue. In patients with severe compression, it was possible to identify an impression of the facial nerve at the REZ after the decompression procedure (Fig. 4D).

In some cases, the AMRs disappeared when the cerebrospinal fluid was aspirated after incision of the dura mater, even before the decompression procedure was performed. In the majority of cases, the AMRs disappeared when the offending blood vessel was moved (Fig. 3B) and, after confirming the disappearance of AMRs, the decompression procedure was concluded. If the AMRs persisted even after the vessel that had been identified as compressing the REZ of the facial nerve was moved, the pontobulbar junction area was checked between



**Fig. 2** Electrode placement used to record the abnormal muscle responses in patients undergoing microvascular decompression to relieve hemifacial spasm.

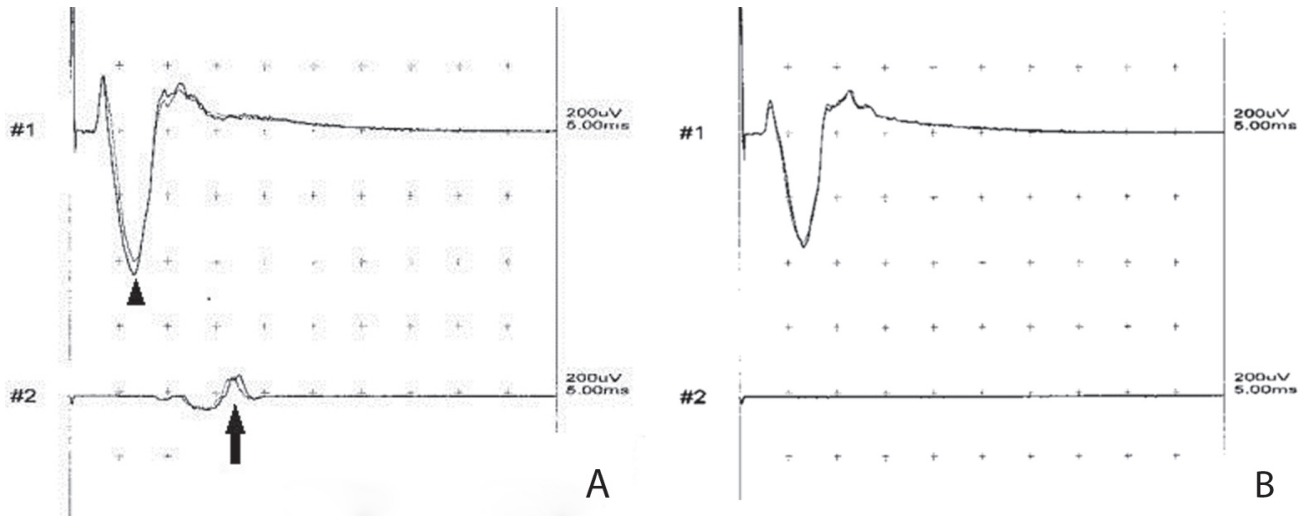


Fig. 3 A: Electromyograms recorded before decompression showing a normal muscle response recorded from orbicularis oculi muscle (top row; *arrowhead*) and an abnormal muscle response recorded from mentalis muscle (bottom row; *arrow*). B: Electromyograms recorded after decompression in the same patient as in A, in which abnormal muscle responses are no longer seen.

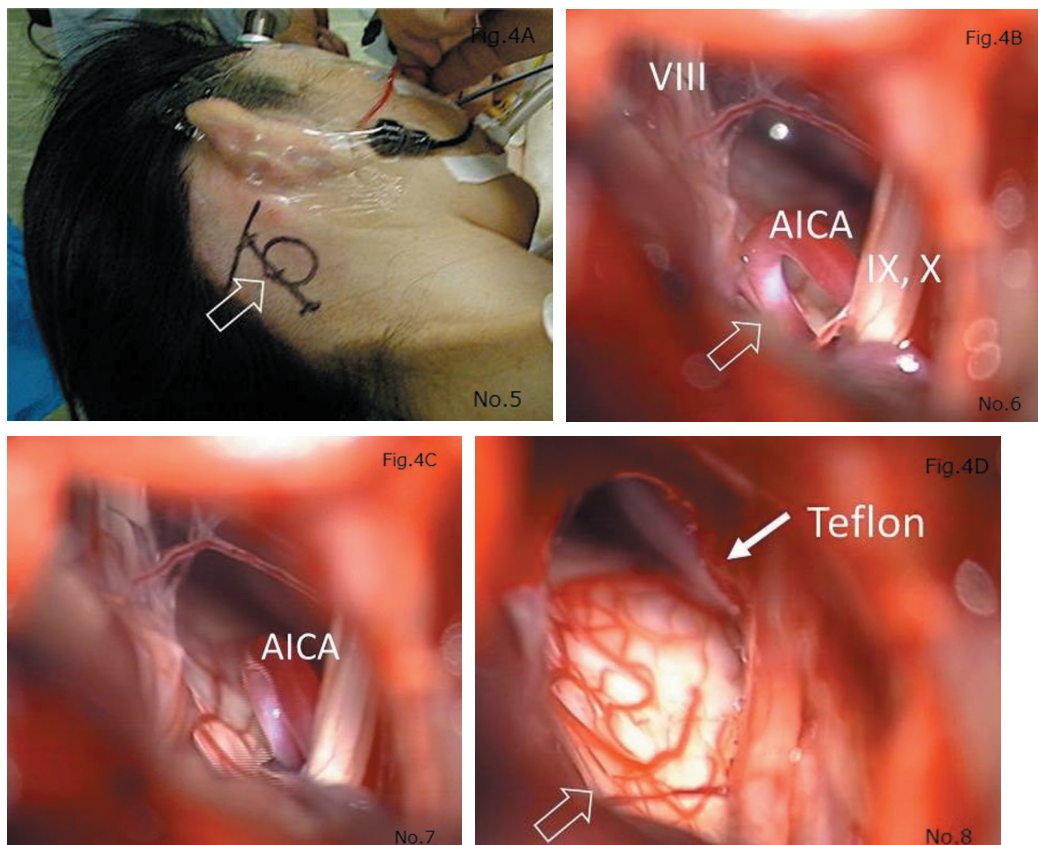


Fig. 4 Intraoperative photographs of microvascular decompression for right hemifacial spasm A: *Arrow* indicates skin incision and site of the craniotomy. B: *Arrow* indicates the posterior inferior cerebellar artery that is compressing on the root exit zone of the facial nerve. VIII: Acoustic nerve. IX: Glossopharyngeal nerve. X: Vagus nerve. C: The anterior inferior cerebellar artery (AICA) after anterior translocation with a spatula. D: The translocated anterior inferior cerebellar artery held in place with Teflon. Digitation is visible at the origin of the facial nerve (*open arrow*).

the lower cranial nerves. If a blood vessel was found to be compressing the facial nerve on the bulbar side, the offending blood vessel was moved toward the petrous bone. If the AMRs persisted even after this vessel was moved, the periphery of the facial nerve was checked, and arteries that passed between the auditory nerve and facial nerve were moved as far peripherally as possible so that no vessels came into contact with the area around the facial nerve REZ. If the AMRs still persisted, it was judged to be a case of persistent AMRs, and the decompression procedure was concluded. An earphone was inserted in the patient's ear on the affected side, and electrodes for recording the auditory brainstem response were placed on the vertex and close to the ear. When the absolute latency of the V wave of this response was prolonged to 1.0 ms or more, surgery was suspended to prevent auditory nerve damage.<sup>19)</sup>

Postoperative spasms were evaluated both at 1 week and 1 year postsurgery, and the severity of spasms was classified according to the four-point postoperative grade of involuntary movement scale described by Kondo et al.<sup>5)</sup> (Table 1). A comprehensive analysis of the surgical outcome, including complications, was performed at 1 year postsurgery based on the analysis described by Kondo et al.<sup>5)</sup> (Table 1).

Cases were classed as either "AMR-disappearance" if the AMR disappeared in response to decompression, or "persistent-AMR" if the AMR persisted until the end of the operation, even when decompression had

been continued beyond the REZ. Age, sex, side of lesion, type of offending blood vessel, and surgical outcomes were compared across groups using  $\chi^2$  tests or unpaired *t* tests. *P*-values < 0.05 were judged to indicate a significant difference between groups.

## Results

One hundred and eighteen cases (90%) were classed as AMR-disappearance. The AMR disappeared after cerebrospinal fluid aspiration following incising the dura (*n* = 24), after decompression of the site that was judged to be the REZ of the facial nerve (*n* = 77), or after additional decompression beyond the REZ (*n* = 17). Thirteen cases (10%) were classed as persistent-AMR. Age, sex, side of lesion, and type of offending blood vessel were similar in AMR-disappearance and persistent-AMR groups (Table 2). The amplitude of the AMR after decompression was lower than before decompression even in the persistent-AMR group, and the mean amplitude was 39% (range 20–55%).

The spasms of all patients ceased immediately after surgery, but (42%) they recurred from 1 to 3 days (mean  $\pm$  standard deviation, 2.1  $\pm$  0.7 days) postsurgery (Fig. 5) in 55 patients. In all these recurrent cases, however, spasms were milder than before surgery and gradually decreased in severity. At 1 year postsurgery spasms were classed as E-0 (*n* = 119, 91%), E-1 (*n* = 8, 6%), or E-2 (*n* = 4, 3%). No patients had spasms of E-3 severity.

The edges of the surgical wound failed to completely fuse in eight cases, and cerebrospinal fluid rhinorrhea occurred in two cases. No cases of permanent

**Table 1 Classification according to the four-point postoperative grade of involuntary movement scale and comprehensive analysis of the surgical outcome, including complications (by Kondo et al.<sup>5)</sup>)**

Evaluation of postoperative grade of involuntary movement (E)
E-0: Complete disappearance of spasm
E-1: Occasional slight spasm
E-2: Moderate spasm, apparently persisting
E-3: Not cured
Evaluation of complications (C)
C-0: No deficits, or only slight subjective complaints
C-1: Slight cranial nerve or cerebellar dysfunction, not bothersome for daily life
C-2: Both subjective and objective cranial nerve or cerebellar dysfunction, problematic for daily life
Total evaluation of results (T): The sum of the E and C grades
T-0: Excellent
T-1: Good
T-2: Fair
T-3 to T-5: Poor

**Table 2 Characteristics of patients in the AMR-disappearance group and the persistent-AMR group**

	Disappearance	Persistent	<i>P</i> -value
Patient, <i>n</i>	118 (90%)	13 (10%)	
Mean age, <i>y</i>	55.9	57.3	0.58
Sex, male:female	36:82	4:9	0.76
Location, right:left	57:61	6:7	0.88
Offending vessel, <i>n</i> (%)			0.81
AICA	38 (32%)	5 (38%)	
PICA	26 (22%)	3 (23%)	
AICA + PICA	9 (8%)	2 (15%)	
AICA + VA	21 (18%)	2 (15%)	
PICA + VA	16 (14%)	1 (8%)	
Others	8 (7%)	0 (0%)	

AICA: anterior inferior cerebellar artery, AMR: abnormal muscle response, PICA: posterior inferior cerebellar artery, VA: vertebral artery, *y*: years.

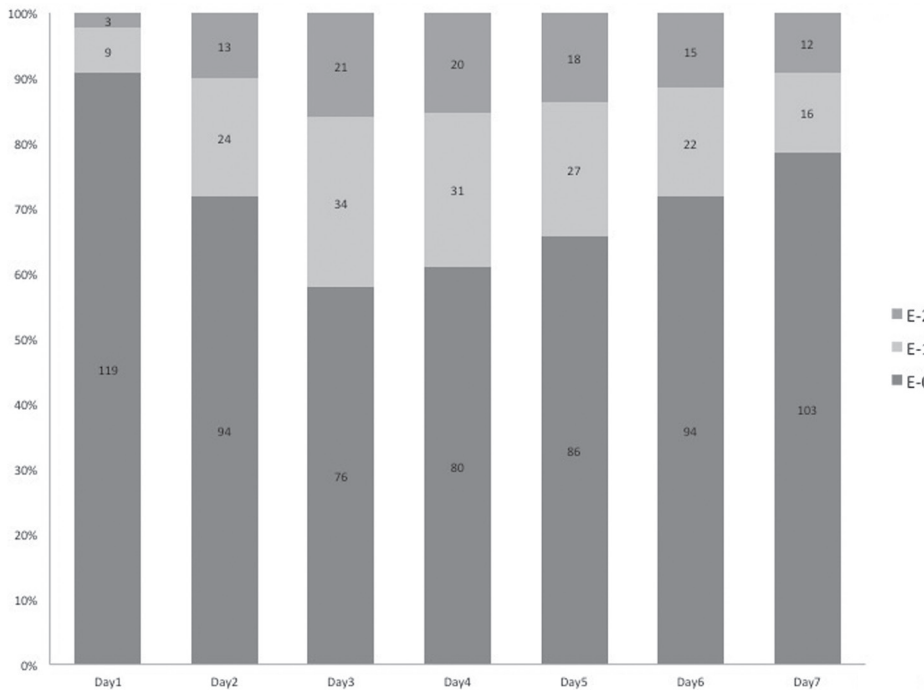
cranial nerve or cerebellar functional deficits were observed. Accordingly, the comprehensive evaluation of surgical outcome was T-0 in 119 cases (91%), T-1 in eight cases (6%), and T-2 in four cases (3%). No cases were classed as T-3, T-4, or T-5. The decompression process was prolonged in the AMR-disappearance subgroup in which additional decompression was performed beyond the REZ and in the persistent-AMR group and, accordingly, the average duration of surgery was 18 min longer in these cases. The ABR did become intraoperatively worse in any case; additionally, no postoperative complications developed as a result of the additional decompression in any case.

At 1 week postsurgery, spasms had ceased in 82% of cases in the AMR-disappearance group and 46% of cases in the persistent-AMR group. Mild (E-1) spasms were present in 10% of cases in the AMR-disappearance group and 31% in the persistent-AMR

group, and moderate (E-2) spasms were present in 8% of cases in AMR-disappearance group and 23% of cases in the persistent-AMR group. The proportion of patients who had no or mild spasms was significantly higher in the AMR-disappearance group than in the persistent-AMR group ( $P < 0.05$ ; Table 3, Fig. 6A).

At 1 year postsurgery, spasms had ceased in 92% of cases in the AMR-disappearance group and 84% of the cases in the persistent-AMR group. Mild (E-1) spasms were present in 6% of cases in the AMR-disappearance group and 8% of the cases in the persistent-AMR group, and moderate (E-2) spasms were present in 3% of cases in the AMR-disappearance group and 8% of the cases in the persistent-AMR group. These percentages were similar in the two groups ( $P = 0.56$ ; Table 3, Fig. 6B).

In the AMR-disappearance group, the degree of postoperative improvement of the spasms was similar



**Fig. 5** The number of patients who exhibited moderate (E-2; *mid-gray*), mild (E-1; *light gray*), and absent (E-0; *dark gray*) spasms in the early postoperative period, spasms recurred (E-1 and E-2) in 55 patients (42%) by Day 3, but gradually improved thereafter and only 28 patients (17%) had spasms on Day 7.

**Table 3** Postoperative grade of involuntary movement in the AMR-disappearance group and the persistent-AMR group

	One week after surgery		One year after surgery	
	Disappearance	Persistence	Disappearance	Persistence
E0	97 (82%)	6 (46%)	108 (92%)	11 (84%)
E1	12 (10%)	4 (31%)	7 (6%)	1 (8%)
E2	9 (8%)	3 (23%)	3 (3%)	1 (8%)
E3	0 (0%)	0 (0%)	0 (0%)	0 (0%)
<i>P</i> -value	$P < 0.05$		N.S.	

AMR: abnormal muscle response, N.S.: not significant.

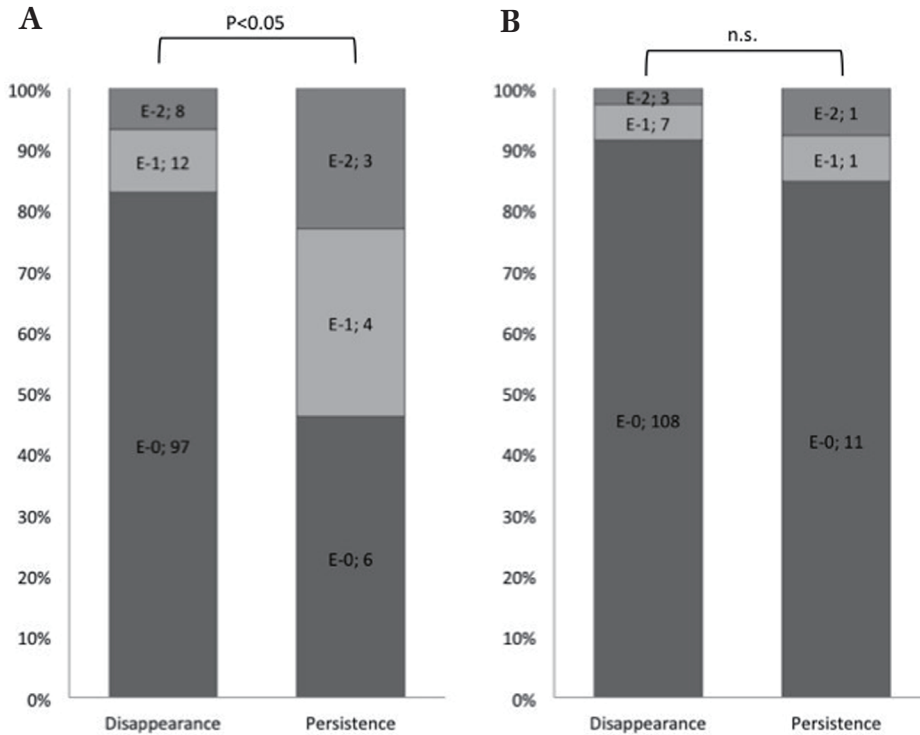


Fig. 6 The number of patients in the persistent-AMR group and the AMR-disappearance group who exhibited moderate (E-2; mid-gray), mild (E-1; light gray), and absent (E-0; dark gray) spasms at 1 week (A) and 1 year (B) postoperatively. At 1 week postoperatively, the number of patients with onset of spasms (E-1 and E-2) was significantly higher in the persistent-AMR group compared to the AMR-disappearance group (Fig. 6A), but no significant intergroup difference was seen at 1 year postoperatively (Fig. 6B). n.s.: not significant.

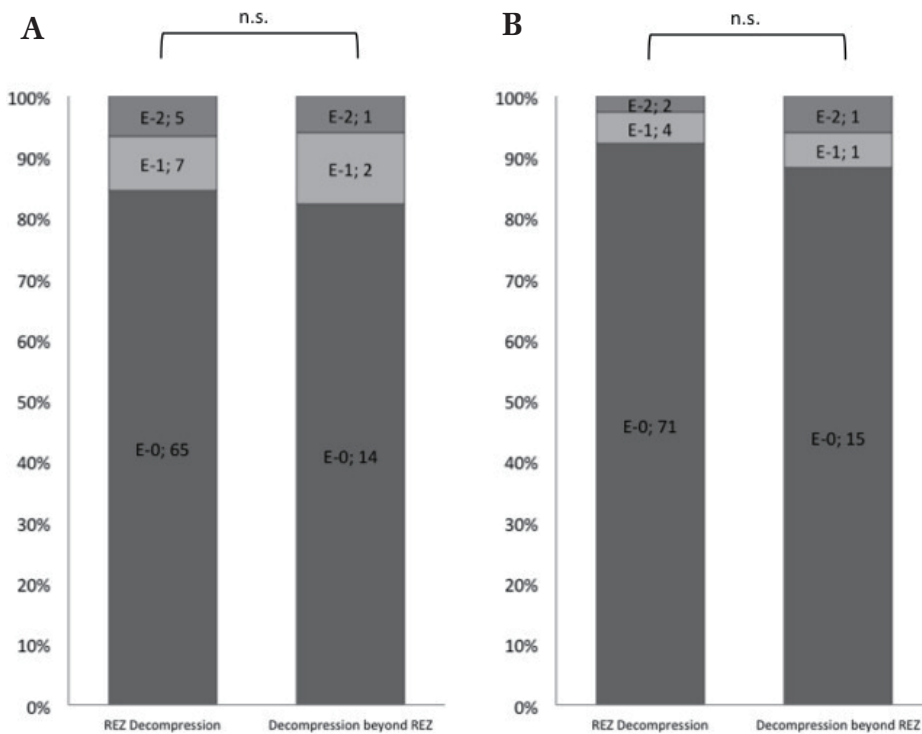


Fig. 7 The number of patients in the REZ Decompression group (AMR disappeared following decompression of the REZ) and the Decompression beyond REZ group (AMR disappeared following additional decompression beyond the REZ) who exhibited moderate (E-2; mid-gray), mild (E-1; light gray), and absent (E-0; dark gray) spasms at 1 week (A) and 1 year (B) postoperatively. Comparison of patients in whom AMR disappeared following decompression of the REZ and those in whom AMR disappeared following additional decompression beyond the REZ showed no significant intergroup differences in the onset of spasms at both 1 week (Fig. 7A) and 1 year (Fig. 7B) after surgery. AMR: abnormal muscle response, n.s.: not significant, REZ: root exit zone.

in the cases in which the AMR disappeared after decompression of the REZ and the cases in which AMR disappeared after additional decompression

beyond the REZ at 1 week ( $P = 0.94$ ) and 1 year ( $P = 0.77$ ) postsurgery (Fig. 7).

## Discussion

There is seldom confusion in identifying the offending blood vessel at the REZ during MVD, but on rare occasions it is difficult to identify the offending vessel with certainty. It may not be possible to visually determine which vessel is causing the hemifacial spasm if several vessels are in contact with the facial nerve. AMRs can be recorded in most patients and disappear within a few seconds after the compression is relieved; they also provide a quantitative indicator of decompression.<sup>4,10,12,13,15,17,20</sup> When more than one blood vessel is in contact with the facial nerve, intraoperative monitoring of AMRs can prevent complications such as hearing disorders or facial nerve paralysis that are caused by unnecessary decompression of blood vessels that are not responsible for the spasm.<sup>18</sup> However, cases have been reported in which AMRs persist even after decompression has been performed. The reported incidence of such cases varies widely, from 7% to 47%,<sup>2,3,7,10,12,13,18,20,21</sup> presumably because the decompression procedures have varied between studies. For example, in the report by Shin et al.,<sup>13</sup> the persistent-AMR rate was 47%, and only 71% of these cases experienced long-term resolution of spasms, but cases in which the decompression procedure was incomplete may have been included in this group. In the current study, our basic procedure was to continue to perform decompression until the AMRs disappeared and, as a result, the persistent-AMR rate was only 10%, and 85% of these cases experienced long-term resolution of spasms. Similarly, in other reports of low persistent-AMR rates,<sup>7,10,12,18</sup> the search for blood vessels causing compression was widened when the AMRs failed to disappear after the initial decompression. These results suggest that when decompression procedures are performed carefully, a persistent-AMR rate of 10–20% is reasonable. The risk of complication by nerve damage increases when the search for blood vessels is widened because the duration of surgery increases. Therefore, it is important to perform the procedure gently and monitor the auditory brainstem response to prevent auditory nerve damage.

Improvement or resolution of spasm has previously been reported in persistent-AMR cases, but the reported incidence has varied widely, from 68% to 100%.<sup>2,3,7,10,12,13,18,20,21</sup> This is likely due, at least in part, to the fact that the duration of follow-up ranged from 3 to 60 months, as has been suggested by a meta-analysis.<sup>12</sup> In this study, we used a follow-up period of 1 year. We consider this to be sufficient as spasms resolve in the majority of cases by this

time point.<sup>5,22</sup> The wide range in the rate of spasm resolution among persistent-AMR cases may also be due to the fact that a standardized scale has not been used to evaluate the degree of improvement in facial spasms. Sekula et al.<sup>12</sup> reported a high postoperative cure rate, but they classified the disappearance of 90% or more of the spasms as a cure; therefore, cases in which mild spasms persisted may have been included. Shin et al.<sup>13</sup> stated that a standardized classification method is needed to make accurate postoperative evaluations. The evaluation method proposed by Kondo et al.<sup>5</sup> contains a classification method that is simple and easy to understand, and has been recommended by the Japan Society for Microvascular Decompression Surgery. Moreover, because it evaluates symptoms 1 year postoperatively and judges postoperative outcome by an overall score that includes whether or not there are postoperative complications, it is useful for making comparisons with other methods of treatment for hemifacial spasm, such as botulinum toxin. This is the first report to have used this evaluation method to assess the cure rate of persistent-AMR cases, and the cure rate 1 year after surgery was 85%. Similar cure rates have been reported by other studies,<sup>7,21</sup> and we believe these values represent the true cure rate of persistent-AMR patients at 1 year postsurgery.

The persistence of AMR after decompression does not necessarily predict a poor long-term outcome. This may be due to inter-individual differences in the cause of the hemifacial spasms. For example, if the primary cause of the hemifacial spasm is spontaneous or ectopic excitation of the facial nerve in response to pulsatile compression, the AMRs will disappear soon after decompression.<sup>15</sup> However, if restoration of the firing threshold, remyelination of the facial nerve, or the degree of hyperexcitation in the facial nerve nucleus underlies the hemifacial spasms, the AMRs may persist immediately after decompression and take some time to disappear.<sup>15,17,21,22</sup> AMRs occur as a result of cross-transmission at sites of compression,<sup>7</sup> and because AMRs are not thought to reflect all of the pathological changes responsible for facial spasms, it is impossible to rule out the possibility that the degree of spasm resolution and AMR disappearance are not related.

Even if AMRs do not disappear, a strong possibility remains that the symptoms will resolve if AMR amplitude during surgery decreases as a result of the decompression procedure.<sup>23</sup> A change in AMR amplitude during surgery also appears to be an indication for a successful decompression procedure.<sup>8,23</sup> AMR amplitude was found to have

decreased in all 13 cases in the persistent-AMR group, supporting the results of Møller et al.<sup>14)</sup> The mechanism of decrease in the amplitude is unclear, but is presumably due to a reduction in the number of hyperexcited neurons that has been caused by a decrease in antidromic stimulation of the facial nucleus after the compression has been relieved, rather than to the persistence of blood vessels causing compression. In this study, AMRs were not recorded after the operation. We hypothesize that recording the change in AMR amplitude from pre- to postsurgery will lead to new knowledge on spasm resolution in persistent-AMR cases.

The reappearance of spasms was observed in 42% of all cases by 3 days postoperation. Ishikawa et al.<sup>22)</sup> reported that spasms reappeared in 88 of the 175 cases (50%) by 4 days postoperation, and more than half of these disappeared within 1 month; however, 7% continued for 1 year or more. Thus, there is a phenomenon in which a spasm that temporarily disappears after the operation can reappear. This may be due to a recovery of the systemic condition in the few days after surgery and a return to preoperative postures and activities of daily living that causes indirect mild compression through adjacent decompression material or the pulsation of cerebrospinal fluid at the sites of decompression. Spasms would then reappear until the demyelination is repaired. In addition, it is possible that intraoperative decompression of the facial nerve causes mild facial paresis, which could mask any postoperative spasms, and the balance between hyperexcitability and peripheral damage of the facial nerve can therefore be considered to be involved in the reappearance of spasm after surgery.<sup>22)</sup>

In the present study, the long-term outcome of decompression surgery in which the AMR persisted was no different to that of decompression surgery in which the AMR intraoperatively disappeared. However, the AMR disappeared after additional decompression beyond the REZ in 17 patients, and additional decompression resulted in the same recovery rate as when the AMR disappeared after decompression of the REZ. Therefore, continuing the search for the blood vessels that were causing compression when the AMR did not disappear eliminated persistent-AMR cases that might have resulted from either the compressing vessel being missed or incomplete decompression, and thus resulted in a low incidence of persistent-AMR. These results indicate that intraoperative AMR monitoring is useful for both judging the effectiveness of facial nerve decompression and preventing offending blood vessels from remaining undiscovered.

## Acknowledgments

The authors would like to thank Kyouji Nozaka for analyzing clinical data. The authors would also like to thank Chiaki Kudo for providing support.

## Conflicts of Interest Disclosure

The authors report no conflict of interest concerning the materials or methods used in this study or the findings specified in this article.

Author contributions to the study and manuscript preparation are as follows. Conception and design: all authors. Acquisition of data: all authors. Analysis and interpretation of data: all authors. Drafting the article: all authors. Critically revising the article: all authors. Reviewed final version of manuscript and approved it for submission: all authors.

## References

- 1) Jannetta PJ, Abbasy M, Maroon JC, Ramos FM, Albin MS: Etiology and definitive microsurgical treatment of hemifacial spasm. Operative techniques and results in 47 patients. *J Neurosurg* 47: 321–328, 1977
- 2) Hatem J, Sindou M, Vial C: Intraoperative monitoring of facial EMG responses during microvascular decompression for hemifacial spasm. Prognostic value for long-term outcome: a study in a 33-patient series. *Br J Neurosurg* 15: 496–499, 2001
- 3) Hyun SJ, Kong DS, Park K: Microvascular decompression for treating hemifacial spasm: lessons learned from a prospective study of 1,174 operations. *Neurosurg Rev* 33: 325–334; discussion 334, 2010
- 4) Isu T, Kamada K, Mabuchi S, Kitaoka A, Ito T, Koiwa M, Abe H: Intra-operative monitoring by facial electromyographic responses during microvascular decompressive surgery for hemifacial spasm. *Acta Neurochir (Wien)* 138: 19–23; discussion 23, 1996
- 5) Kondo A, Date I, Endo S, Fujii K, Fujii Y, Fujimaki T, Hasegawa M, Hatayama T, Hongo K, Inoue T, Ishikawa M, Ito M, Kayama T, Kohmura E, Matsushima T, Munemoto S, Nagahiro S, Ohno K, Okamura T, Ryu H, Shigeno T, Shirane R, Tagusagawa Y, Tanabe H, Yamada K, Yamakami I: A proposal for standardized analysis of the results of microvascular decompression for trigeminal neuralgia and hemifacial spasm. *Acta Neurochir* 154: 773–778, 2012 (*in press*)
- 6) Nagahiro S, Takada A, Matsukado Y, Ushio Y: Microvascular decompression for hemifacial spasm. Patterns of vascular compression in unsuccessfully operated patients. *J Neurosurg* 75: 388–392, 1991
- 7) Yamashita S, Kawaguchi T, Fukuda M, Watanabe M, Tanaka R, Kameyama S: Abnormal muscle response monitoring during microvascular decompression for hemifacial spasm. *Acta Neurochir (Wien)* 147:



- 933–937; discussion 937–938, 2005
- 8) Fukuda M, Yamashita S, Kawaguchi T, Watanabe M, Murakami H, Takao T, Tanaka R: [Abnormal muscle response monitoring during microvascular decompression for hemifacial spasm and long term results]. *No Shinkei Geka* 34: 583–589, 2006 (Japanese)
  - 9) Kim CH, Kong DS, Lee JA, Kwan-Park: The potential value of the disappearance of the lateral spread response during microvascular decompression for predicting the clinical outcome of hemifacial spasms: a prospective study. *Neurosurgery* 67: 1581–1587; discussion 1587–1588, 2010
  - 10) Mooij JJ, Mustafa MK, van Weerden TW: Hemifacial spasm: intraoperative electromyographic monitoring as a guide for microvascular decompression. *Neurosurgery* 49: 1365–1370; discussion 1370–1371, 2001
  - 11) Neves DO, Lefaucheur JP, de Andrade DC, Hattou M, Ahdab R, Ayache SS, Le Guerinel C, Keravel Y: A reappraisal of the value of lateral spread response monitoring in the treatment of hemifacial spasm by microvascular decompression. *J Neurol Neurosurg Psychiatry* 80: 1375–1380, 2009
  - 12) Sekula RF Jr, Bhatia S, Frederickson AM, Jannetta PJ, Quigley MR, Small GA, Breisinger R: Utility of intraoperative electromyography in microvascular decompression for hemifacial spasm: a meta-analysis. *Neurosurg Focus* 27: E10, 2009
  - 13) Shin JC, Chung UH, Kim YC, Park CI: Prospective study of microvascular decompression in hemifacial spasm. *Neurosurgery* 40: 730–734; discussion 734–735, 1997
  - 14) Møller AR: Neurophysiological monitoring in cranial nerve surgery. *Neurosurg Quarterly* 5: 55–72, 1995
  - 15) Møller AR, Jannetta PJ: Microvascular decompression in hemifacial spasm: intraoperative electrophysiological observations. *Neurosurgery* 16: 612–618, 1985
  - 16) Møller AR, Jannetta PJ: Monitoring facial EMG responses during microvascular decompression operations for hemifacial spasm. *J Neurosurg* 66: 681–685, 1987
  - 17) Huang BR, Chang CN, Hsu JC: Intraoperative electrophysiological monitoring in microvascular decompression for hemifacial spasm. *J Clin Neurosci* 16: 209–213, 2009
  - 18) Thirumala PD, Shah AC, Nikonow TN, Habeych ME, Balzer JR, Crammond DJ, Burkhart L, Chang YF, Gardner P, Kassam AB, Horowitz MB: Microvascular decompression for hemifacial spasm: evaluating outcome prognosticators including the value of intraoperative lateral spread response monitoring and clinical characteristics in 293 patients. *J Clin Neurophysiol* 28: 56–66, 2011
  - 19) Hatayama T, Moller AR: Correlation between latency and amplitude of peak V in the brainstem auditory evoked potentials: intraoperative recordings in microvascular decompression operations. *Acta Neurochir (Wien)* 140: 681–687, 1998
  - 20) Kong DS, Park K, Shin BG, Lee JA, Eum DO: Prognostic value of the lateral spread response for intraoperative electromyography monitoring of the facial musculature during microvascular decompression for hemifacial spasm. *J Neurosurg* 106: 384–387, 2007
  - 21) Joo WI, Lee KJ, Park HK, Chough CK, Rha HK: Prognostic value of intra-operative lateral spread response monitoring during microvascular decompression in patients with hemifacial spasm. *J Clin Neurosci* 15: 1335–1339, 2008
  - 22) Ishikawa M, Nakanishi T, Takamiya Y, Namiki J: Delayed resolution of residual hemifacial spasm after microvascular decompression operations. *Neurosurgery* 49: 847–854; discussion 854–856, 2001
  - 23) Møller AR, Jannetta PJ: On the origin of synkinesis in hemifacial spasm: results of intracranial recordings. *J Neurosurg* 61: 569–576, 1984

---

*Address reprint requests to:* Hana Tobishima, MD, Department of Neurosurgery, Hirosaki University School of Medicine, Zaihu-cho, Hirosaki, Aomori 036-8562, Japan.  
*e-mail:* nougeka@cc.hirosaki-u.ac.jp