

Immunohistological Analysis of Eotaxin and RANTES in the Model
Animal of Eosinophilic Otitis Media.

(好酸球性中耳炎モデル動物における Eotaxin と RANTES の免疫組織
学的分析)

申請者 弘前大学大学院医学研究科
感覚統合科学領域耳鼻咽喉・頭頸部外科学教育研究分野

氏 名 工 藤 直 美

指導教授 松 原 篤

Abstract

Background: The most crucial clinical problem of Eosinophilic Otitis Media (EOM) is sensorineural hearing loss. Our previous report revealed that repeated antigen stimulation of middle ear causes eosinophilic inflammation not only in the middle ear but also in the inner ear. **Objective:** The purpose of the present study was to elucidate the mechanism of eosinophil infiltration to the inner ear in the animal model of EOM.

Methods: Continuous OVA stimulation to the middle ear of guinea pigs was performed for 7 days, 14 days, and 28 days. Histological observation was made for eosinophil infiltration and morphological change of the inner ear. Immunostaining for eotaxin and RANTES was performed to study immunoreactivity of those chemokines.

Results: In the 7-day stimulation side, a few eosinophils were found in the scala tympani, without obvious morphological damage of the inner ear. Moreover, immunoreactivity of both eotaxin and RANTES was significantly higher in the OVA stimulation sides than control sides. For both eotaxin and RANTES, the number of immunopositive cells was significantly increased in 14-day stimulation side than 7-day stimulation side.

Conclusions: Eotaxin and RANTES seem to play some important roles for the eosinophil infiltration in the middle and inner ear of model animal of EOM.

Key words:

eosinophil, scala tympani, round window membrane, eotaxin, RANTES

Acknowledgments

This study was supported by a Grant-in-aid Scientific Research (C: 16K11169, 24592537 to AM) from the Ministry of Education, Science, Sports, and Culture of Japan.

Declaration of interest

The authors report no conflicts of interest. The authors alone are responsible for the content and writing of the paper.

Introduction

Eosinophilic Otitis Media (EOM) is an intractable otitis media characterized by eosinophil-enriched highly viscous middle ear effusion, and it is often associated with bronchial asthma and nasal polyposis. Tomioka firstly named the type of otitis media EOM [1], and the diagnostic criteria for EOM was established by EOM study group in 2011 [2]. Today it is widely recognized as a middle ear disease induced by eosinophilic inflammation [3, 4, 5].

EOM is known to be a high risk disease often involving severe sensory hearing loss. It has been reported that the incidence of deterioration of bone conducting hearing loss (BCHL) was significantly higher than in the common type otitis media [6]. BCHL of EOM is progressive unless treated appropriately, and as the duration of the subjective symptom prolongs, the risk of BCHL increases [6, 7]. Because severe hearing loss exerts negative influences on patients' quality of life, it is critically important to clarify the pathophysiology of eosinophilic inflammation of the middle ear as well as the inner ear.

Eotaxin and RANTES are known as chemokines which attract eosinophils and prompt allergic inflammation [8]. These chemokines have been reported to exist in nasal polyps, leading to characteristic infiltration by eosinophils in chronic rhinitis [9, 10]. Both eotaxin and RANTES have been reported to be found from middle ear effusion or middle ear mucosa epithelial cells of EOM patients [11, 12]. In the present study, we attempted immunostaining for eotaxin and RANTES in the middle ear and the inner ear of the animal model to explore how the two chemokines involve in the pathological process of eosinophilic inflammation of EOM.

Histological and immunohistological study is one of the promising approaches, in which we can directly observe the morphological change of middle ear and inner ear. We can also study what kind of factor is involved in the pathophysiological process of EOM. However, it is difficult to use the specimens from clinical cases, especially inner ear, for the purpose of such an experimental study. Nishizawa et al [13] constructed an animal model of EOM and this method enables us to make morphological and experimental study of EOM. It has been also reported that morphological damage was observed in the inner ear of the animal models [14]. However, it is still unclear how eosinophils infiltrate to the inner ear. In the present study, we performed

immunostaining for eotaxin and RANTES to investigate their distribution in the temporal bone specimens, and to consider the mechanism of the inner ear damage in the animal model of EOM.

Material and methods

Tissue preparation

In the present study, we used the sections of the temporal bone specimens dissected from the animal model constructed in the previous study reported by Nishizawa et al. [13]. Briefly, 15 Hartley Guinea Pigs (250g to 350g) were generally sensitized by intraperitoneal injection of OVA (Wako 014-17074) 2000 μ g and aluminum hydroxide (alum) 100mg on day 0, and 100 μ g OVA and 100mg alum on days 7 and 14. From day 21, they were topically boosted by daily application of OVA solution; 100 μ g OVA for nasal drip, and 0.1 ml OVA (1000 μ g/ml) for intratympanic injection into the right ear (OVA stimulation side). 0.1ml saline was injected to intratympanic space of the left ear for control from day 21. The daily application of OVA and saline were continued for 7 days (n=5), 14 days (n=5), and 28 days (n=5). All procedures were carried out under anesthesia with sodium pentobarbital (20mg/kg i.p.). After the final OVA injection, they were deeply anesthetized with sodium pentobarbital (50mg/kg i.p.) and injected intratympanically with 10% formaldehyde. Then the temporal bones were dissected and postfixed with 10% formaldehyde (4 hr), and decalcified with EDTA2Na in 0.1M TRIS (pH7.2). Then, paraffin-embedded sections (3 μ m) were prepared and stained with hematoxylin-eosin.

Immunohistology

The sections were deparaffinized through xylene, then rehydrated through a graded series of ethanol to phosphate-buffered saline (PBS) and incubated in the following solutions: (1) 0.3% H₂O₂ for 30 min, (2) Protein Block Serum-Free (DAKO, Code X0909) for 30 min, (3) anti-eotaxin-3 polyclonal antibody (abcam® 1:400), and anti-RANTES polyclonal antibody (abcam® 1:400) and 1% bovine serum albumin in PBS at 4°C overnight, (4) reagents of Envision/HRP (rabbit) for 30 min, and (5) diaminobenzine/H₂O₂ for 5 min. Sections

were rinsed well with PBS between steps. Immunostained sections were counterstained with hematoxylin and examined under a light microscope.

As the control study, anti-eotaxin antibody and eotaxin peptide (abcam®), anti-RANTES antibody and RANTES peptide (abcam®), were mixed respectively. We performed the same process of immunostaining using the mixture instead of each primary antibody. Immunoreactivity for eotaxin and RANTES was not detected in either experiment.

Cell count and statistical analysis

The sections were observed by an Olympus microscope (BX51), and assessed by digital images using a digital camera (Olympus DP72) and imaging software (DP2-BSW). The number of immunopositive cells for eotaxin-3 and RANTES, was counted per unit area (0.01mm^2) in the submucosal area of the middle ear in five areas for five model animals each, and the results were analyzed statistically.

Unpaired *t*-test was performed using Stat Mate ver. 4.01 (ATMS, Tokyo, Japan), to compare the OVA stimulation side and control side. A probability value (*p*) less than 0.05 was considered statistically significant.

All animal experiments in this paper followed the Guidelines for Animal Experimentation, Hirosaki University.

Results

No obvious morphological damage was found in the inner ear of 7-day stimulation side, and the Organ of Corti was well-preserved (Fig. 1A). A few eosinophils were observed in the scala tympani, in this early period of antigen stimulation (Fig. 1B). In the 28-day stimulation side, obvious morphological damage was observed and there were numerous inflammatory cells such as eosinophils, lymphocytes, plasma cells, neutrophils, and macrophages in the scala tympani (Fig. 1C, D). Severe morphological damage of the organ of Corti also found in this period of stimulation.

The thickness of mucosa was increased as the OVA stimulation became longer (Fig 2A, B), and the number of cells such as eosinophils, plasma cells, lymphocytes infiltrated, and plenty of fibroblasts were also observed

in the middle ear mucosa of 14-day stimulation side (Fig 2B). Immunoreactivity for eotaxin-3 was apparently low in the control side (Fig.3A). In the 7-day stimulation side, the eotaxin-3 immunoreactivity among the epithelial cells and fibroblast-like cells of the submucosal area increased (Fig.3B). In the 14- and 28-day stimulation sides (Fig.3C, D), the eotaxin-3 immunoreactivity was also observed in not only fibroblast-like cells but also other type of inflammatory cells. Moreover, the number of immunopositive cells in the 14-day stimulation side was significantly larger than that in the 7-day stimulation side. On the other hand, there found no immunopositive cells around the scala tympani in the 7-day stimulation side as well as control side (Fig.3E, F). Although we also performed immunostaining for eotaxin-1 and eotaxin-2 (data not shown), immunoreactivity of eotaxin-3 was prominent, thus we examined data on eotaxin-3.

RANTES positive cells in the middle ear mucosa are fewer than eotaxin positive cells. However, we found immunopositive cells increased when the period of stimulation became longer (Fig 4). RANTES immunoreactivity in the inner ear was not observed, the same as eotaxin-3 (data not shown).

Statistical analysis of eotaxin-3 and RANTES in the submucosal area of middle ear is shown in Fig 4. Eotaxin-3 positive cells were observed (mean + SD: $14.9 + 1.57$) per unit area in the 7-day stimulation side, and (mean + SD: $20.2 + 5.08$) cells per unit area are found in 14-day stimulation side. The number of immunopositive cells is significantly larger than 7-day stimulation side. In the 28-day stimulation side, (mean + SD: $20.1 + 4.19$) immunopositive cells per unit area are found, which is not significantly different from 14-day stimulation side (Fig.5A).

As for RANTES, $2.2 + 0.75$ immunopositive cells were found in the 7day stimulation side, and $4.7 + 1.22$ cells in the 14-day stimulation side. We found a significant difference between 7-day stimulation side and 14-day stimulation side. In the 28-day stimulation side, only $3.9 + 4.11$ immunopositive cells are found, which has no significant difference from 14-day stimulation side (Fig 5B). RANTES positive cells were far fewer than eotaxin positive cells.

Discussion

Deterioration of bone conduction hearing is one of the striking clinical features of EOM, but its pathophysiology is still unclear. In the recent report, antigen specific IgE in the middle ear effusion was detected, which suggests that some kind of antigen stimulation would be one factor of pathogenesis [15]. As we described so far in our animal model of EOM [14], the number of eosinophils infiltrating to the perilymphatic space of the inner ear increased as the periods of antigen stimulation by OVA to the middle ear became longer. Moreover, severe morphological damage to the organ of Corti was observed in the long time antigen stimulation. These results indicated that eosinophilic inflammation occurred in the inner ear as well as in the middle ear, consequently developing BCHL. Then what is the mechanism of infiltration of eosinophils to the inner ear?

OVA stimulation to the middle ear causes allergic reaction, in which eotaxin produced by the epithelial cells and by the number of cells in the thickened middle ear mucosa, play some important role of recruiting eosinophils to the middle ear mucosa and middle ear cavity. As the period of antigen stimulation became longer, the middle ear mucosa became thicker [13], and severe morphological damage and infiltration by plenty of inflammatory cells including eosinophils, neutrophils, lymphocytes, plasma cells, occurred in the inner ear [14]. Therefore, it seems that our animal model reflects clinical pathology of inner ear damage of EOM.

We demonstrated the immunoreactivity of eotaxin-3 was found in the epithelial cells and the number of cells in the thickened middle ear mucosa. It is believed that fibroblasts synthesize eotaxin in nasal polyp [16]. Therefore, it seemed that epithelial cells and fibroblasts might play an important role for producing eotaxin and recruitment of eosinophils in 7-day stimulation model. As the period of stimulation became longer, inflammatory cells like eosinophils, plasma cells, lymphocytes, and vascular endothelial cells may also involve producing eotaxin [17].

It is well known that chemokines like eotaxin promote eosinophil infiltration in allergic disease. The previous study has shown that eotaxin concentration in the middle ear effusion of EOM patients was significantly higher than control groups [11] [12]. In our previous reports, the number of eosinophils significantly increased after 2-week stimulation. In contrast, eotaxin positive cells started to increase significantly from 1-week. These results

would suggest that secretion of eotaxin precedes eosinophil increase in the middle ear consequently involving eosinophil infiltration to the middle ear and establishing the pathophysiological condition.

Immunoreactivity of RANTES was also significantly higher in both 7-day stimulation sides and 14-day stimulation sides. However, the number of immunoreactive cells is less than eotaxin. Also, a previous study reported that RANTES concentration in the middle ear effusion of EOM patients and its immunoreactivity showed no significant difference from control group [12]. These results would suggest that, in the pathophysiology of EOM, eotaxin might have a greater role than RANTES.

Although a few eosinophils were observed in the perilymphatic space in the early period (7-day) antigen stimulation side, no immunoreactivities of eotaxin was observed in the scala tympani. Moreover, no morphological damage of middle ear and inner ear was detected. Then the question is how the eosinophils were recruited to the perilymphatic space. From the results of our study, we assume eotaxin and RANTES pass through the round window membrane (RWM). RWM is proved to be permeable to the Lipopolysaccharide (LPS), the molecular weight of which is at least 5000 [18]. The molecular size of chemokines such as eotaxin and RANTES is 8-14 kDa, which is smaller than LPS. Therefore, it seems conceivable to speculate that chemokines penetrate to the inner ear through RWM and attract eosinophils to the perilymphatic space of the scala tympani. By long duration of OVA stimulation, the concentration of eotaxin and RANTES becomes higher, and those chemokines penetrate to the perilymphatic space through RWM.

It seems difficult to explain the inner ear damage through the effects of chemokine alone. However, the existence of these chemoattractants in the middle ear could be one important factor of eosinophil infiltration to the inner ear, for at least in the early period. The statement of deafness might be formed by the progression of inflammatory reaction induced by eosinophils and other inflammatory cells in the middle ear as well as in the inner ear, and consequently RWM might be destructed. Further study is needed to reveal the accurate mechanism.

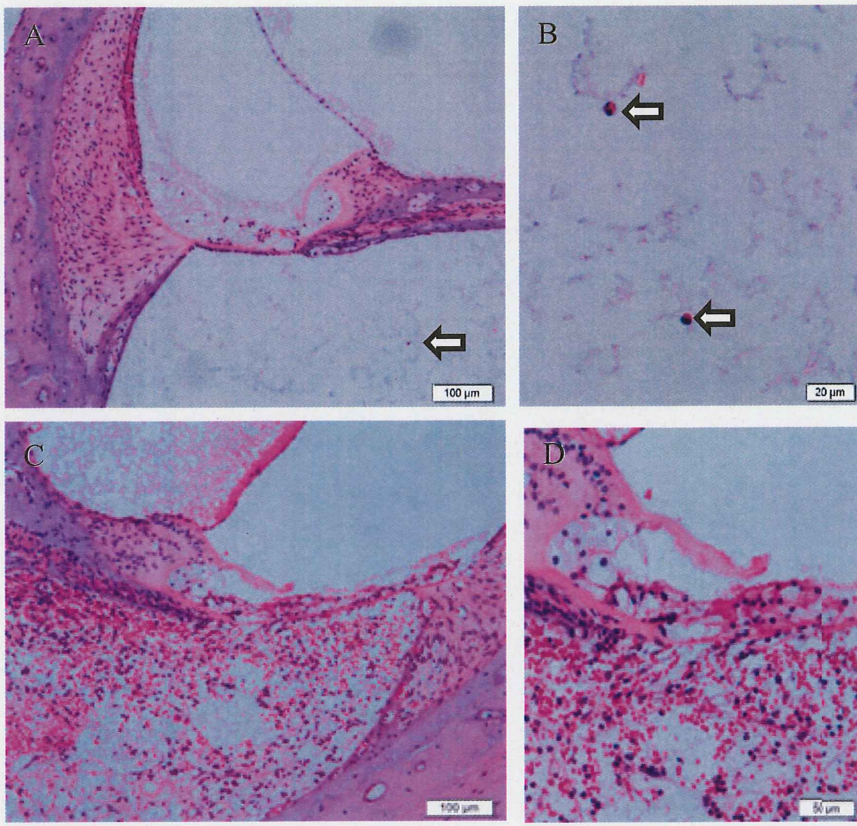
Figure 1

Figure 1 Histological sections of the inner ear from 7-day and 28day (H-E staining). Morphological structure of the inner ear is well-preserved in 7-day OVA stimulation side (A). Remarkably, a few eosinophils (arrows) were already seen in the scala tympani (A, B). The scala tympani under high power field (B). Inner ear of 28-day OVA stimulation side was obviously damaged, accompanied with infiltration of numerous eosinophils and other inflammatory cells in the scala tympani (C, D). The organ of Corti under high power field (D).

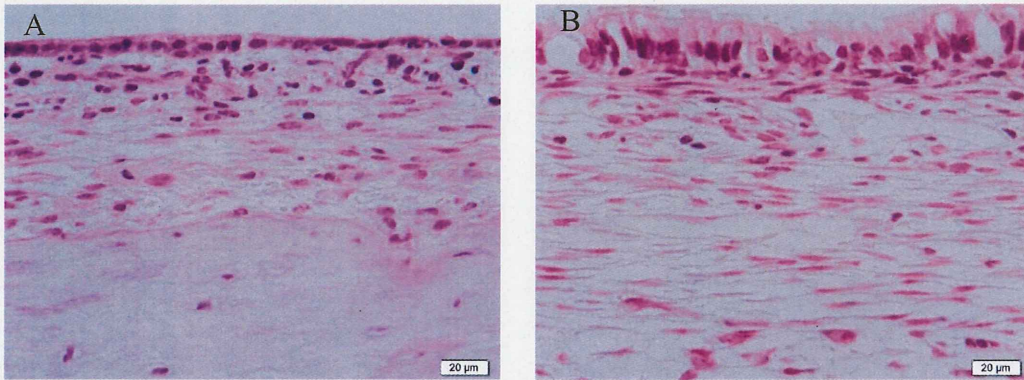
Figure 2

Figure 2 Histological sections of the middle ear from 7-day and 14-day stimulation sides (H-E staining). In the 7-day stimulation side, fibroblasts and a few inflammatory cells such as eosinophils were observed (A). The middle ear mucosa became thicker in 14-day stimulation side, and the number of fibroblasts and inflammatory cells increased (B).

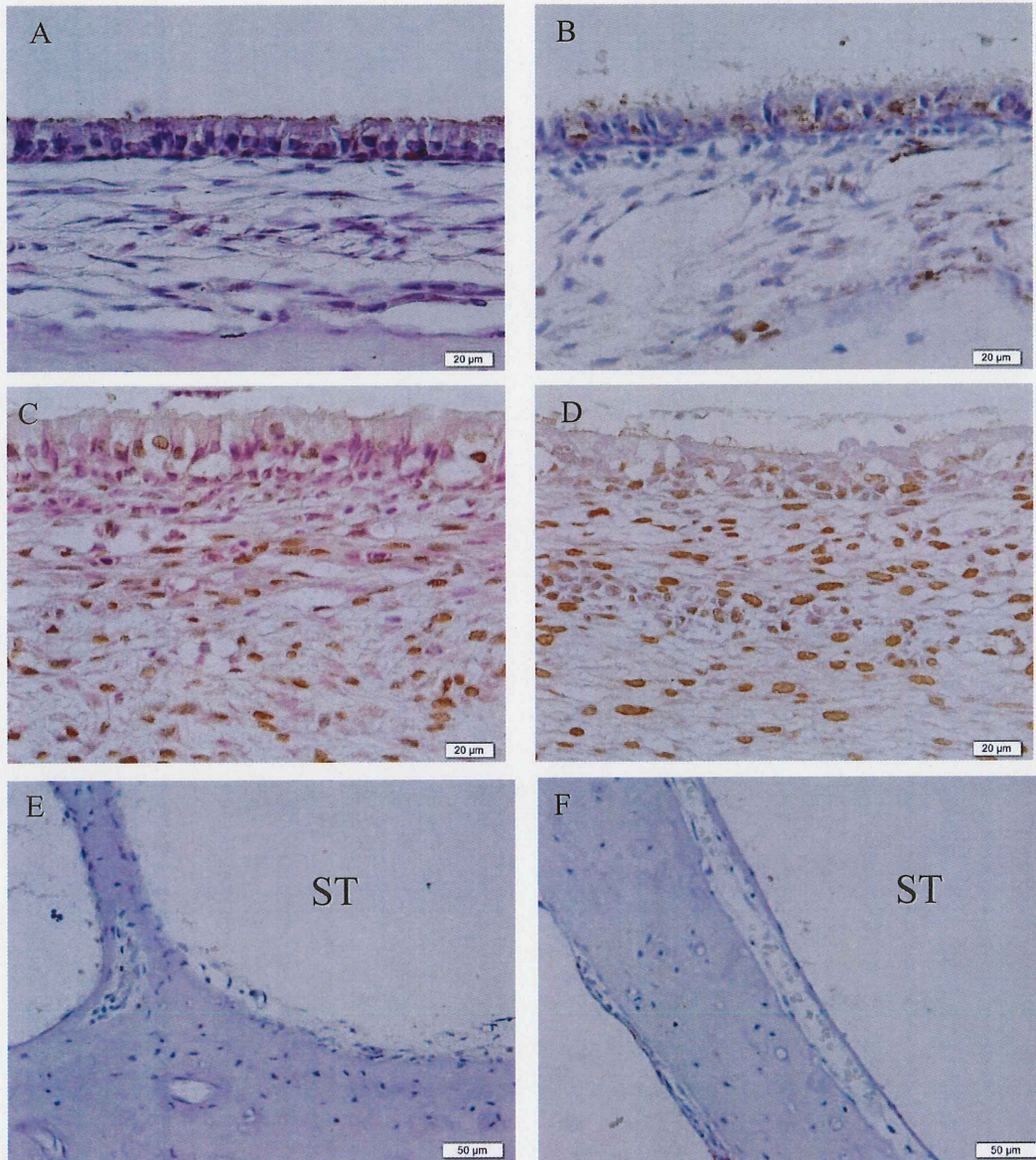
Figure 3

Figure 3 Immunohistological sections of the middle ear and the inner ear for eotaxin-3. There found few immunopositive cells in control side (A). Note that immunoreactivity for eotaxin-3 was observed in some epithelial cells and fibroblasts-like cells of the submucosa in the 7-day stimulation side (B). The number of immunopositive cells increased in the 14-day (C), and 28-day (D) OVA stimulation sides. Eotaxin-3 immunoreactivity was not found in the Scala tympani (ST) both control side (E) and stimulation side (F) for 7 days.

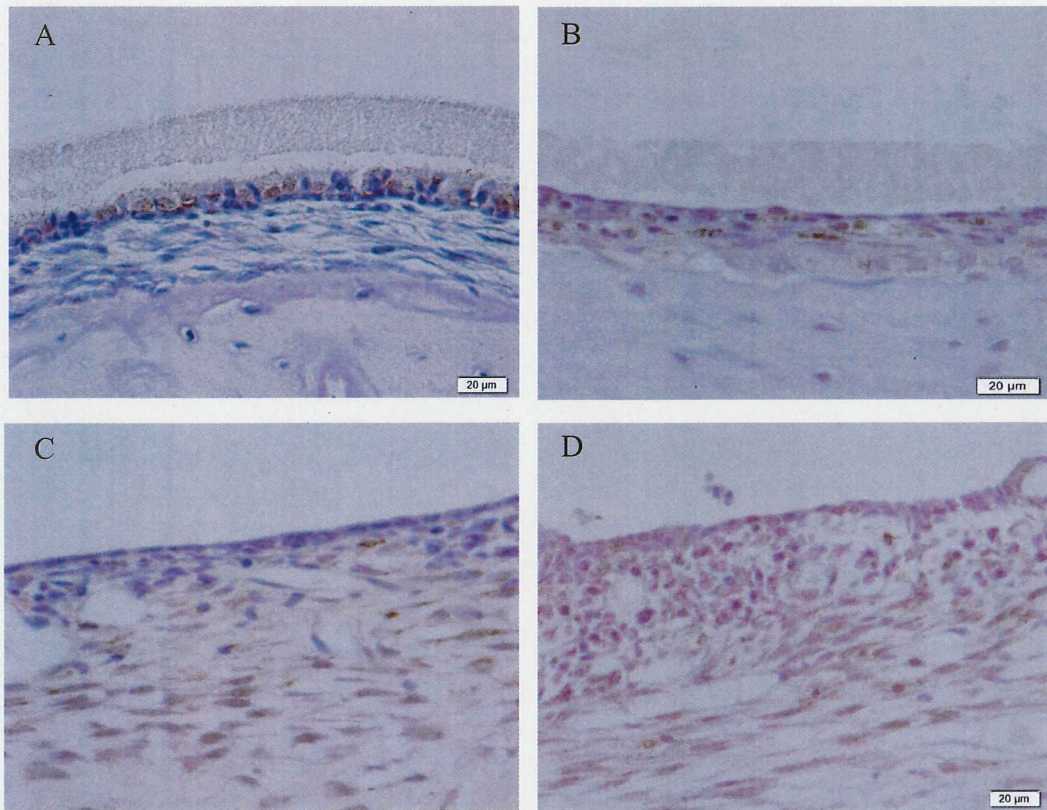
Figure 4

Figure 4 Immunohistological sections of the middle ear for RANTES. Immunoreactivity for RANTES was slightly observed in the epithelial cells in the control side (A). Note that more immunopositive cells were observed in the submucosa in the 7-day stimulation side (B), and immunopositive cells were obviously increased in the 14-day (C) and 28-day (D) stimulation sides.

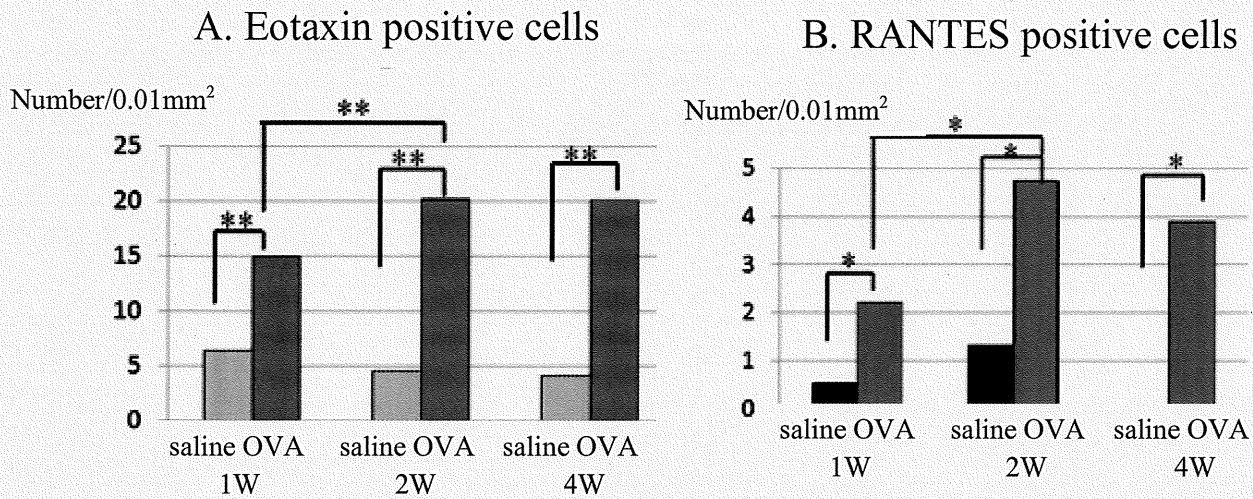
Figure 5

Figure 5 Statistical analysis of the number of immuno-positive cells for Eotaxin-3 (A), RANTES (B) in the submucosal area of the middle ear (/0.01mm²). In the both chemokines, immunopositive cells were increased in the OVA stimulation sides than control sides (saline). Immunoreactivity was significantly higher in 14-day stimulation sides than 7-day stimulation sides (n=5, mean, *: P<0.01, **: P<0.001).

References

- [1] Tomioka S, Kobayashi T, Takasaka T. Intractable otitis media in patients with bronchial asthma (eosinophilic otitis media). In: Sanna M, editor. Cholesteatoma and mastoid surgery. Rome: CIC Edizioni Internazionali 1997; 851-3.
- [2] Iino Y, Tomioka-Matsutani S, Matsubara A, Nakagawa T, Nonaka M. Diagnostic criteria of eosinophilic otitis media, a newly recognized middle ear disease. *Auris Nasus Larynx* 2011; 38:456-61.
- [3] Liu Y, Zhang Z, The eosinophilic otitis media's research progress. *Lin Chung Er Bi Yan Hou Tou Jing Wai Ke Za Zhi* 2015 Sep; 29(17): 1577-80. Chinese
- [4] de Jong MA, Smithuis LO, Stokross RJ, Eosinophilic otitis media. *Ned Tijdschr Geneesk.* 2014; 158: A8044. Dutch.
- [5] Azadarmaki R, Westra W, Prasad S. Eosinophilic Mucin Otomastoiditis and Otopolyposis: A Progressive Form of Eosinophilic Otitis Media. *Ann Otol Rhinol Laryngol.* 2015 Sept; 124 (9): 752-6
- [6] Iino Y, Usubuchi H, Kodama K, Takizawa K, Kanazawa T, and Ohta Y. Bone conduction Hearing level in Patients with eosinophilic otitis media associated with bronchial asthma. *Otology and Neurotology* 2008; 29: 949-52.
- [7] Nakagawa T, Matsubara A, Shiratsuchi H, Kakazu Y, Nakashima T, Koike K. Intractable otitis media with eosinophils: importance of diagnosis and validity of treatment for hearing preservation. *ORL* 2006; 68: 118-22
- [8] Jose PJ, Griffiths-Jonson DA, Collins PD, Walsh DT, Moqbel R, Totty NF, Truong O, Hsuan JJ, Williams TJ. Eotaxin: A Potent Eosinophil Chemoattractant Cytokine Detected in a Guinea Pig Model of Allergic Airways Inflammation. *J. Exp. Med.* 1994 Mar; 179: 881-7
- [9] Bartels J, Maune S, Meyer JE, Kulke R, Schluter C, Rowert J, Christophers E, Schroder JM. Increased eotaxin-m RNA expression in non-atopic and atopic nasal polyps: comparison to RANTES and MCP-3 expression. *Rhinology* 1997 Dec; 35(4): 171-4
- [10] Baraniuk JN. Pathogenesis of allergic rhinitis. *J Allergy Clin. Immunol.* 1997 Feb; 99(2): S763-72
- [11] Nonaka M, Fukumoto A, Ozu C, Mokuno E, Baba S, Pawankar R, et al. IL-5 and eotaxin levels in middle ear effusion and blood from asthmatics with otitis media with effusion. *Acta Otolaryngol* 2003; 123: 383-7.

- [12] Iino Y, Kakizaki K, Katano H, Saigusa H, Kanegasaki S. Eosinophil chemoattractants in the middle ear of patients with eosinophilic otitis media. *Clin Exp Allergy* 2005; 35:1370-6.
- [13] Nishizawa H, Matsubara A, Nakagawa T, Ohta N, Izuhara K, Shirasaki T, et al. The role of periostin in eosinophilic otitis media. *Acta Otolaryngol* 2012; 132: 838-44.
- [14] Matsubara A, Nishizawa H, Kurose A, Nakagawa T, Takahata J, Sasaki A. An experimental study of inner ear injury in an animal model of eosinophilic otitis media. *Acta Otolaryngol* 2014; 134: 227-32.
- [15] Kanazawa H, Yoshida N, Shinnabe A and Iino Y. Antigen-specific IgE in middle ear effusion of patients with eosinophilic otitis media. *Ann Allergy Asthma Immunol* 2014; 113(1): 88-92
- [16] Nonaka M, Pawankar R, Saji F, Yagi T, Eotaxin synthesis by nasal polyp fibroblasts. *Acta Otolaryngol* 1999; 119: 816-20.
- [17] Yao T, Kojima Y, Koyanagi A, Yokoi H, Saito T, Kawano K et al. Eotaxin-1, -2, -3 Immunoreactivity and Protein Concentration in the Nasal Polyps of Eosinophilic Chronic Rhinosinusitis Patients. *The Laryngoscope* 2009; 119: 1053–59
- [18] Takumida M. Mechanism and treatment of the inner ear disorders in otitis media. *Otology Japan* 2004; 14: 36-8