

CASE REPORT

Macular Hole Caused by Retained Subfoveal Perfluorocarbon that Subsequently Closed After Its Spontaneous Resolution: A Case Report

Reiko Tanabu · Yukihiro Suzuki · Kaori Suzuki · Shizuka Takahashi · Mitsuru Nakazawa · Hideyuki Mizutani

Received: August 4, 2017 / Published online: September 20, 2017
© The Author(s) 2017. This article is an open access publication

ABSTRACT

Introduction: To prevent local reduction in retinal function caused by retained subretinal perfluorocarbon liquid (PFCL), it has been noted that removal of PFCL under the fovea should be considered, with a vitrectomy selected for such removal.

Case Report: A vitrectomy was performed for traumatic retinal detachment during which PFCL was temporarily used as an intraocular tamponade for retina flattening. Following surgery, subfoveal PFCL was retained beneath the retina. Two months later, a macular hole developed and visual acuity decreased to 20/100, for which a vitrectomy was planned as treatment. However, the macular hole spontaneously closed and visual acuity eventually recovered to 20/25.

Conclusion: Our findings indicate that PFCL retained underneath the retina in the macular region can cause a macular hole, though

spontaneous discharge may subsequently occur, leading to resolution.

Keywords: Macular hole; Optical coherence tomography; Perfluorocarbon; Retinal detachment

INTRODUCTION

We performed a vitrectomy for traumatic retinal detachment in a teenage boy. Following the procedure, a macular hole developed from residual perfluorocarbon liquid (PFCL) droplets remaining in the retina. A second vitrectomy was planned; however, the PFCL spontaneously extruded, leading to natural closure of the macular hole. The course was followed by optical coherence tomography (OCT), and the details are reported here.

CASE REPORT

A 14-year-old boy was struck in the right eye with a baseball, which caused traumatic hyphema, cataract, vitreous hemorrhage, and retinal detachment. We performed primary surgical procedures, during which cataract surgery and a vitrectomy were completed. During the operation, PFCL was temporarily injected into the vitreous cavity for flattening the retina below, which was extensively detached. At the

Enhanced content To view enhanced content for this article go to <http://www.medengine.com/Redeem/390CF0602F29EDAB>.

R. Tanabu · Y. Suzuki (✉) · K. Suzuki · S. Takahashi · M. Nakazawa
Department of Ophthalmology, Hirosaki University
Graduate School of Medicine, Hirosaki, Japan
e-mail: yukihiro@hirosaki-u.ac.jp

H. Mizutani
Mizutani Eye Clinic, Aomori, Japan

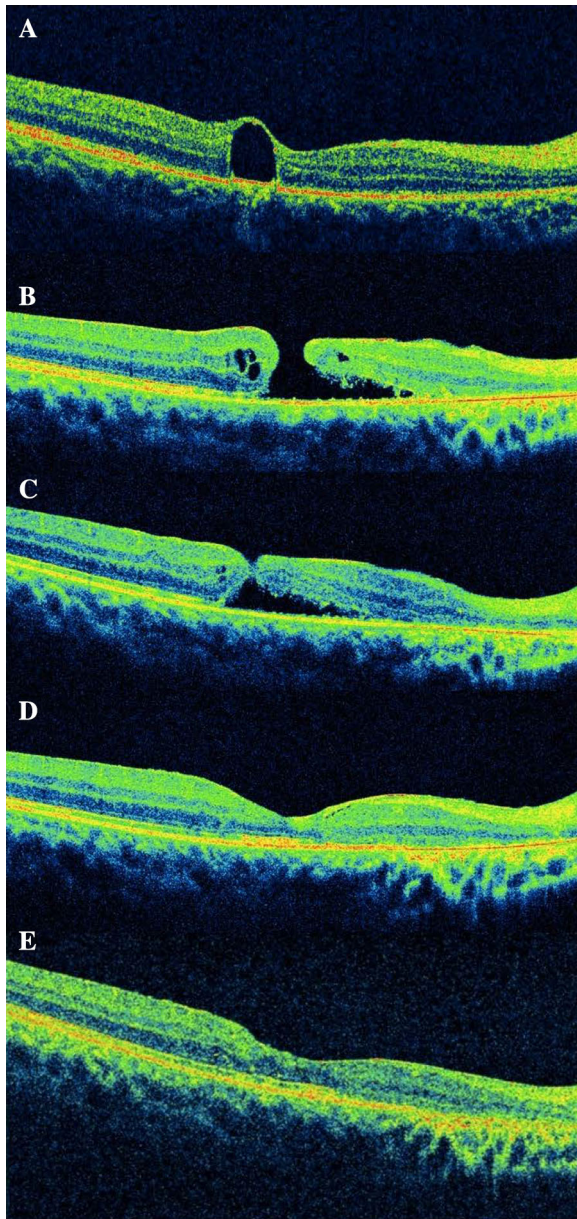


Fig. 1 **a** PFCL droplet remained beneath the retina of the fovea. **b** Two months after the first surgery, a macular hole developed and the droplet formation disappeared. **c** The macular hole spontaneously closed 2 weeks after its formation. **d** One month later, the macular hole formation completely disappeared. **e** Two years later, a macular hole did not recur

completion of surgery, the PFCL was removed with suction and 20% SF₆ gas was injected. Postoperatively, the retina showed reattachment, though PFCL droplets remained beneath

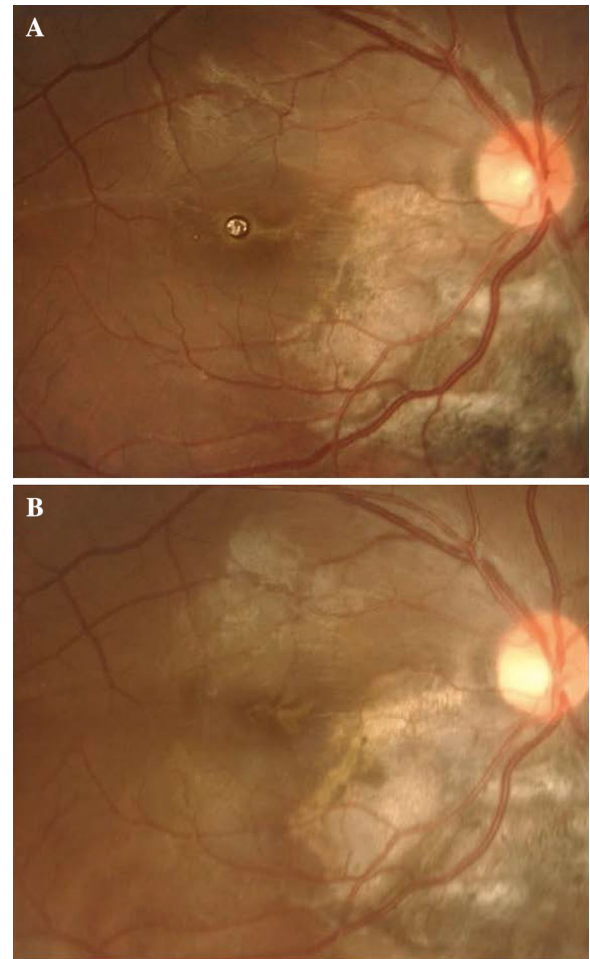


Fig. 2 **a** PFCL droplets remained beneath the retina of the fovea and near the disc. **b** Two months later, the subfoveal PFCL droplet and the macular hole formation disappeared completely

the retina of the fovea (Figs. 1a, 2a). Two months later, a macular hole developed, and the PFCL disappeared (Fig. 1b). Based on our suspicion of a traumatic macular hole, another vitrectomy was planned. Two weeks later, OCT findings confirmed that the macular hole had spontaneously closed, with no recurrence of retinal detachment or macular hole observed since then (Fig. 1c). Furthermore, visual acuity of 20/25 was noted at the most recent follow-up examination (Figs. 1d, e and 2b).

Written informed consent for participation in the study was obtained from the patient's parents.

DISCUSSION

To prevent local reduction in retinal function caused by retained subretinal PFCL, it has been noted that removal of PFCL under the fovea should be considered [1], with a vitrectomy selected for such removal [2, 3]. In a recent report, OCT revealed a residual subfoveal PFCL bubble causing the discontinuity of the ellipsoid zone and disorganization of the retinal pigment epithelium [4]. In other reports, a large PFCL cluster spontaneously migrated from the fovea in a downward direction [5], or a subretinal PFCL droplet subsequently disappeared from the central fovea, resulting in improvement of the retinal structure [6]. In the report, Oellers et al. hypothesized that the PFCL droplet spontaneously extruded through a transient hole created in the thinned retina overlying the droplet, which subsequently closed spontaneously [6].

In the present case, OCT observations revealed formation of a macular hole in our patient that subsequently closed in a spontaneous manner following PFCL disappearance. This occurred after performance of a vitrectomy for traumatic retinal detachment when the retinal structure in the macular region was in a fragile condition, thus subretinal PFCL droplets were likely to discharge more easily as compared to a normal condition. Moreover, in cases in which the internal limiting membrane has already become detached, it is considered that PFCL droplets are more likely to be spontaneously discharged, because the force acting to confine them in a normal retina might be weakened.

ACKNOWLEDGEMENTS

No funding or sponsorship was received for this study or publication of this article. The article processing charges were funded by the authors. All named authors meet the International Committee of Medical Journal Editors (ICMJE) criteria for authorship for the manuscript, take responsibility for the integrity of the work as a

whole, and have given final approval for the version to be published.

Authors contribution RT and YS treated this patient and wrote this report, KS, ST and HM took parts of the postoperative observation and MN took part of the postoperative observation and helped to draft the manuscript. All authors read and approve the final manuscript.

Compliance with ethics guidelines Written informed consent was obtained from the patient's parents for publication of this case report and any accompanying images.

Disclosures Reiko Tanabu, Yukihiro Suzuki, Kaori Suzuki, Shizuka Takahashi, Mitsuru Nakazawa and Hideyuki Mizutani have nothing to disclose.

Open Access This article is distributed under the terms of the Creative Commons Attribution-NonCommercial 4.0 International License (<http://creativecommons.org/licenses/by-nc/4.0/>), which permits any noncommercial use, distribution, and reproduction in any medium, provided you give appropriate credit to the original author(s) and the source, provide a link to the Creative Commons license, and indicate if changes were made.

REFERENCES

1. Tewri A, Elliott D, Singh CN, Garcia-Valenzuela E, Ito Y, Abrams GW. Change in retinal sensitivity from retained subretinal perfluorocarbon liquid. *Retina*. 2009;29:248–50.
2. Roth DB, Sears JE, Lewis Hilel. Removal of retained subfoveal perfluoro-n-octane liquid. *Am J Ophthalmol*. 2004;138:287–9.
3. Shulman M, Sepah YJ, Chang S, Abrams GW, Do DV, Nguyen QD. Management of retained subretinal perfluorocarbon liquid. *Ophthalmic Surg Lasers Imaging Retina*. 2013;44:577–83.
4. Wang H, Chen F, Cao H. Optical coherence tomography angiography characteristics of fovea in residual subfoveal perfluorocarbon liquid eye. *Ophthalmic Surg Lasers Imaging Retina*. 2016;47:1062–6.

-
5. Toth CA, Schneider EW, Folgar FA. Spontaneous peripheral migration of subfoveal perfluorocarbon. *Retina*. 2014;34:2315–6.
 6. Oellers P, Charkoudian LD, Hahn P. Spontaneous resolution of subfoveal perfluorocarbon. *Clin Ophthalmol*. 2015;9:517–9.