

CASE STUDY

**A case of surgery for unicuspid aortic valve with annulo-aortic ectasia**

Zaiqiang Yu, Ikuo Fukuda, Norihiro Kondo, Masahito Minakawa, and Kazuyuki Daitoku

**Abstract** A high percentage of patients with a unicuspid aortic valve require cardiac surgery, because it always induces aortic stenosis or regurgitation. It is sometimes difficult to discriminate it from a bicuspid valve. Here, we report a case of a young patient with severe aortic regurgitation and aortic root enlargement caused by the unicommissural form of unicuspid aortic valve. An aortic valve-sparing operation could not be performed because of his special morphology, and it was thought that sufficient durability could not be obtained postoperatively. The Bentall operation was successfully performed with a mechanical prosthetic valve. His postoperative course was uneventful.

Hirosaki Med. J. 70 : 67–71, 2019

**Key words:** Unicuspid aortic valve; Bentall procedure; Morphology.

**Introduction**

A unicuspid aortic valve (UAV) is a rare congenital aortic valve anomaly seen in 0.02% of the general population (1). A UAV is always combined with aortic stenosis (AS) or aortic regurgitation (AR) or both, which all need surgical intervention. A valve-sparing operation, bicuspidization for a UAV, is an effective surgical procedure, but not for all patients depending on their morphology (2). Here, we report an young patient with a UAV combined with a uni-commissure and without a clear raphe. The Bentall procedure was performed because a valve-sparing operation was not expected to obtain an adequate clinical outcome.

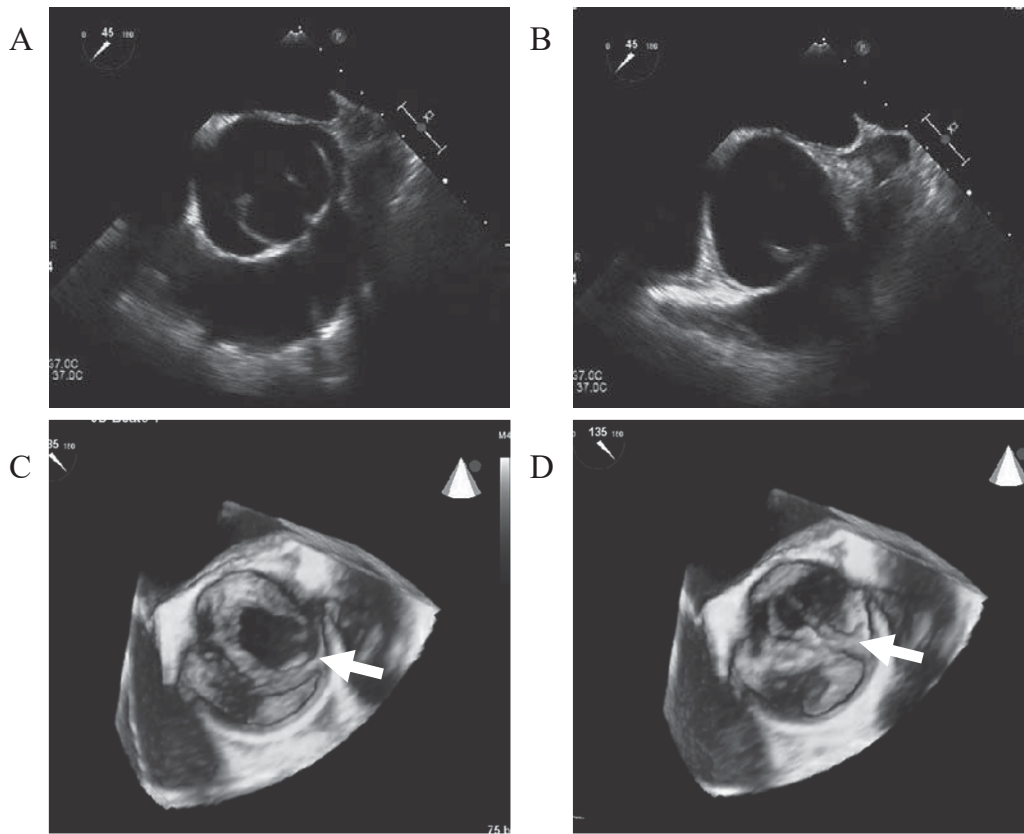
**Case Report**

A 30-year-old man with severe AR and left ventricular enlargement (LVE) was admitted to our hospital. He was 175.6 cm in height and weighed 68.3 kg (body mass index 22.14 kg/

m<sup>2</sup>), with no evidence of Marfan's syndrome. Although he was asymptomatic, a diastolic murmur at the upper right sternal border was found on a health check-up. Transthoracic echocardiography (TTE) and transesophageal echocardiography (TEE) were performed to confirm the condition of the aortic valve and myocardium. TEE showed that he had a UAV (Figure 1). The left ventricular ejection fraction (LVEF) was decreased to 47.1%, and there was severe left ventricular enlargement with a left ventricular end-systolic diameter of 60.0 mm and an end-diastolic diameter of 79.5 mm. TTE and TEE demonstrated severe AR and AS with aortic valve area (AVA) of 1.8 cm<sup>2</sup> and a mean pressure gradient (PG) of 36 mmHg (maximal PG 58 mmHg). Morphologically, the aortic valve was a UAV with a uni-commissure between the left and right coronary cusps. The raphe between the commissures was not clear. Computed tomography (CT) of the chest showed dilatation of the sinus of Valsalva and the ascending aorta with diameters of 49 and 45

Department of Thoracic and Cardiovascular Surgery, Hirosaki University Graduate School of Medicine, Aomori, Japan

Correspondence: Z. Yu  
Received for publication, April 9, 2019  
Accepted for publication, July 22, 2019



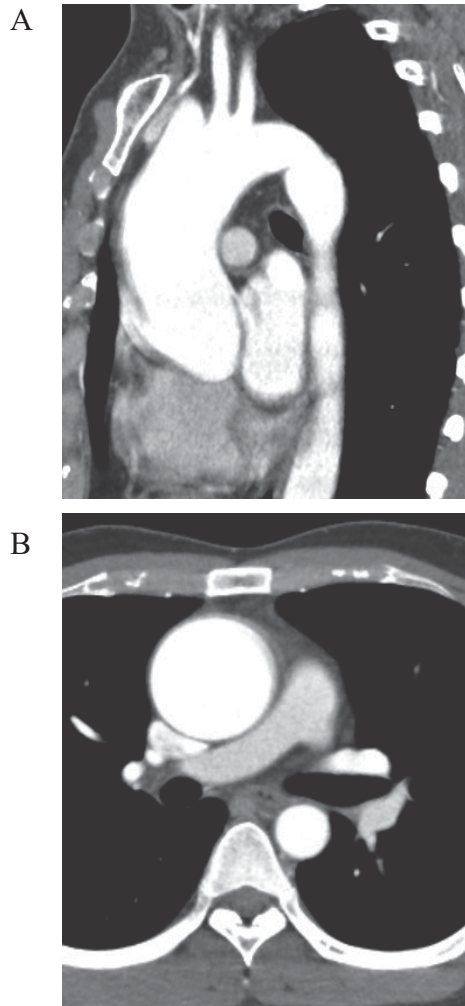
**Figure 1** Unicuspid aortic valve (UAV) without any raphes was seen on transesophageal echocardiography (TEE). The images show UAV like a half fish mouth in the opened condition (A and C, white arrow) and an exclamation point in the closed condition (B and D, white arrow).

mm, respectively (Figure 2). No other morphological anomaly was detected. Valve repair of the unicuspid valve seemed difficult because of unique morphology and no-raphe. This patient underwent the Bentall operation.

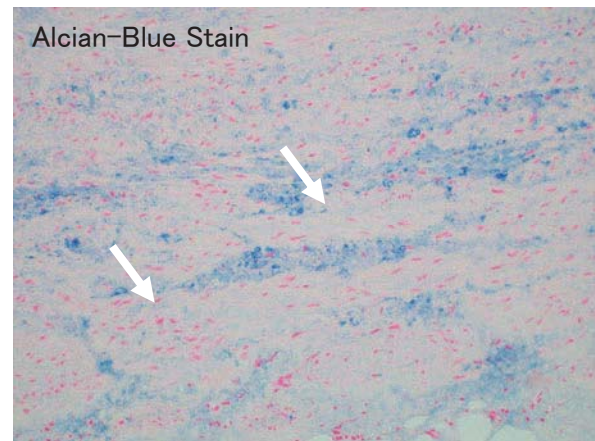
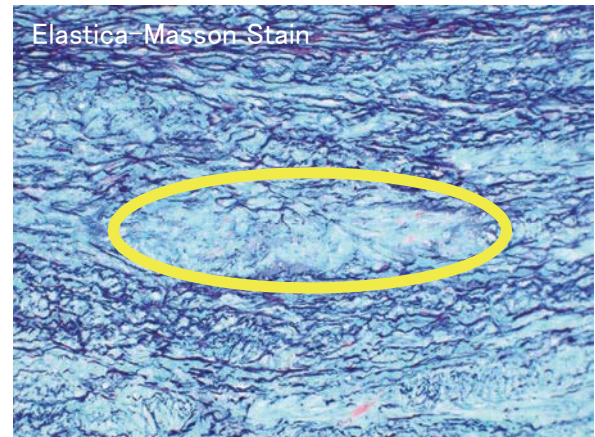
Under hypothermic extracorporeal circulation and cardiac arrest, transverse aortotomy was performed to expose the aortic valve (Figure 3). Morphologically, the aortic valve was unicuspid showing an 'exclamation point' in the closed condition and a 'half fish mouth' in the opened condition. There was only one normal commissure at the left posterior annulus without any raphes. The aortic valve was very thickened with decreased elasticity. Because the morphogenic character of his aortic valve was difficult to repair, the Bentall procedure with a mechanical

prosthetic valve was performed. Hemi-arch replacement was performed simultaneously under deep hypothermic circulatory arrest.

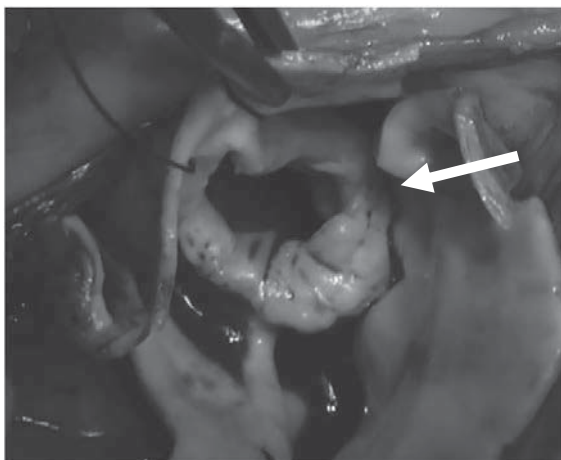
The patient's postoperative course was uneventful. There was partial mild myxoid change in the aortic root, but cystic medial necrosis could not be excluded. Tunica elastica fibers were mildly decreased in the ascending aorta (Figures 4A and 4B). Echocardiography showed no aortic regurgitation one year after the operation. LVEF was 58%, and LV diastolic diameter was 48.5 mm, smaller than preoperative. Improvement of cardiac function was seen one year after operation.



**Figure 2** Contrast computed tomography (CT) showed that the sinus of Valsalva and the ascending aorta were enlarged with diameters of 49 and 45 mm, respectively.



**Figure 4** A: Partial mild myxoid change found in the aortic root, but cystic medial necrosis cannot be excluded (yellow circle). B: Tunica elastic fibers are mildly decreased in the ascending aorta (white arrow).



**Figure 3** There is only one normal commissure (white arrow) at the left posterior annulus without any raphes and like half fish mouth.

## Discussion

UAV was first reported in 1958. Its incidence is supposed to be approximately 0.02%<sup>1,2)</sup>. Although asymptomatic patients with UAV may be found incidentally on preoperative echocardiography for other cardiac diseases, such as a thoracic aortic aneurysm or congenital heart disease<sup>3)</sup>, it always induces symptoms such as dyspnea, because of accelerated calcification<sup>4)</sup>, and left ventricular dysfunction at a younger age than in tricuspid and bicuspid aortic valve patients<sup>5)</sup>. UAV was classified as a subtype of bicuspid aortic valve (BAV) several years ago<sup>6)</sup>; however, UAV is deemed to be a different congenital valve

disease from BAV today because of its higher risk of aortic dilatation and the rapid advancement of valve disease<sup>7</sup>.

Regarding treatment for symptomatic UAV, there are several choices. Aortic valve replacement (AVR) is most commonly performed for aortic valve disease with good clinical outcomes<sup>8</sup>. Because UAV frequently has accelerated calcification, AVR with a mechanical prosthetic valve is standard treatment for young patients. However, there is a high risk of bleeding events induced by anticoagulant medications after AVR. To avoid the risk of bleeding events, valve-sparing operations were developed for young patients with clear raphe, including bicuspidization and tricuspidization procedures<sup>9</sup>. Although calcification was not found in the present case, the aortic valve showed degeneration with fibrosis by pathological diagnosis. There was no clear raphe in this patient. There is another tricuspidization procedure with autologous pericardium-sparing, including creating a new commissure, that was reported by Ozaki<sup>10, 11</sup>, but the long-term outcomes for young patients are unknown. According to a second opinion obtained from Professor Ozaki, because of the patient's special morphology, sufficient durability could not be obtained postoperatively even if a valve-sparing operation were performed. Therefore, the Bentall procedure with a mechanical prosthetic valve was selected.

UAV also shows another characteristic, which is a higher risk for aortopathy in young patients. The patients frequently have histologic changes such as cystic medial necrosis of the aortic wall of the ascending aorta, as well as in the sinuses of Valsalva<sup>12</sup>. A maximum diameter exceeding 45 mm or a maximum area/height ratio over 8 cm<sup>2</sup>/m is an indication for combined operations including AVR and ascending aortic replacement (AAR)<sup>13</sup>. A previous study showed that UAV patients undergoing combined AVR and AAR had better clinical outcomes than patients under-

going valve surgery alone<sup>14</sup>. Ascending aortic dilatation with a stenotic BAV that progresses to the proximal arch after AVR is more frequent than with a TAV as assessed by a 3-dimensional reconstruction tool in our department<sup>15</sup>. We conjectured that separate valve surgery for UAV patients could not prevent progression of aortic dilatation if they had mild enlargement of the ascending aorta, because there were some pathologic changes in the aorta. The present patient showed enlargement of the sinus of Valsalva, the ascending aorta, and the proximal portion of the aortic arch; therefore, the Bentall procedure was performed with hemi-arch replacement. Cystic medial necrosis of the aortic wall was not confirmed on histology postoperatively, but mild myxoid changes were found.

## Conclusion

The degenerative process of a UAV progresses more rapidly at a young age than that of a BAV. The Bentall operation was a durable surgical option for this clinical entity in the present case.

## Informed consent

Informed consent has been obtained from patient for publication of the case report and accompanying images.

## Disclosure Statement

All authors have no conflict of interest.

## Acknowledgements

This research received no specific grant from any funding agency in the public, commercial or not-for-profit sectors.

## Author Contributions

Study conception: all authors

Writing: YZ, IF

Critical review and revision: all authors

Final approval of the article: all authors

Accountability for all aspects of the work: all authors

## References

- 1) Novaro GM, Mishra M, Griffin BP. Incidence and echocardiographic features of congenital unicuspid aortic valve in an adult population. *J Heart Valve Dis.* 2003;12:674-8.
- 2) Schäfers HJ, Aicher D, Riodionychewa S, Lindinger A, Rädle-Hurst T, Langer F, Abdul-Khaliq H, et al. Bicuspidization of the unicuspid aortic valve: a new reconstructive approach. *Ann Thorac Surg.* 2008; 85:2012-8.
- 3) Ermis N, Bilgi M, Altay H, Erol T. An asymptomatic unicuspid aortic valve with aortic aneurysm and secundum type atrial septal defect. *Clin Cardiol.* 2010;33:E38-9.
- 4) Singh S, Ghayal P, Mathur A, Mysliwiec M, Lovoulos C, Solanki P, Klapholz M, et al. Unicuspid unicommissural aortic valve: An extremely rare congenital anomaly. *Tex Heart Inst J.* 2015;42:273-6.
- 5) Higashi H, Ogimoto A, Inoue K, Tokunaga N, Lio C, Aono J, Yoshida S, et al. Eccentric left ventricular hypertrophy in aortic stenosis caused by unicuspid aortic valve. *Circ J.* 2017;81:895-7.
- 6) Sievers HH, Schmidtke C. A classification system for the bicuspid aortic valve from 304 surgical specimens. *J Thorac Cardiovasc Surg.* 2007;133: 1226-33.
- 7) Noly PE, Basmadjian L, Bouhout I, Viet Le VH, Poirier N, El-Hamamsy I. New insights into unicuspid aortic valve disease in adults: Not just a subtype of bicuspid aortic valves. *Can J Cardiol.* 2016;32:110-6.
- 8) Egbe AC, Connolly HM, Poterucha JT, Wames CA. Bicuspid and unicuspid aortic valve: Fate of moderate/severe mixed aortic valve disease. *Congenit Heart Dis.* 2017;12:24-31.
- 9) Abe K, Kawazoe K, Ito J, Yamasaki M, Kuwauchi S, Misumi H. Tricuspidization and reimplantation procedure for unicuspid aortic valve with annuloaortic ectasia. *Ann Thorac Surg.* 2015;99:1095-6.
- 10) Ozaki S, Kawase I, Yamashita H, Uchida S, Nozawa Y, Takatoh M, Hagiwara S. A total of 404 cases of aortic valve reconstruction with glutaraldehyde-treated autologous pericardium. *J Thorac Cardiovasc Surg.* 2014;147:301-6.
- 11) Kawase I, Ozaki S, Yamashita H, Uchida S, Nozawa Y, Matsuyama T, et al. Aortic valve reconstruction of unicuspid aortic valve by tricuspidization using autologous pericardium. *Ann Thorac Surg.* 2012;94:1180-4.
- 12) Agnihotri AK, Desai SC, Lai YQ, Fitzsimons MG, Hilgenberg AD, Vlahakes GJ. Two distinct clinical presentations in adult unicuspid aortic valve. *J Thorac Cardiovasc Surg.* 2006;131:1169-70.
- 13) Svensson LG, Kim KH, Blackstone EH, Rajeswanran J, Gillinov AM, Mihaljevic T, Griffin BP, et al. Bicuspid aortic valve surgery with proactive ascending aorta repair. *J Thorac Cardiovasc Surg.* 2011;142: 622-9.
- 14) Zhu Y, Roselli EE, Idrees JJ, Wojnarski CM, Griffin B, Kalahasti V, Pettersson G, et al. Outcome after operations for unicuspid aortic valve with or without ascending repair in adult. *Ann Thorac Surg.* 2016;101:613-9.
- 15) Hattori K, Fukuda I, Daitoku K, Minakawa M, Itaya H. Rate of stenotic bicuspid aortic valve aortic dilatation after aortic valve replacement, calculated using a 3-dimensional reconstruction tool. *Circ J.* 2017;81:1207-12.