

CASE STUDY

Remarkable effects of salvage chemotherapy with cetuximab and paclitaxel after cancer immunotherapy in two cases of recurrent/metastatic head and neck cancer

Naomi Kudo, Takahisa Abe, Shin Midorikawa, and Atsushi Matsubara

Abstract In recent years, anti-programmed cell death 1 (PD-1) antibody has been approved for recurrent/metastatic head and neck cancer and was reported by the phase 3 study CheckMate 141 to improve the overall survival rate of patients with recurrent/metastatic head and neck squamous cell carcinoma. With the increasing number of cases treated with anti-PD-1 antibody, the synergic interaction between cancer immunotherapy and chemotherapy has been gathering attention. Some reported that administration of chemotherapy after immunotherapy was remarkably effective for progressive non-small cell lung cancer. We examined two notable cases of recurrent/metastatic head and neck cancer in which the subsequent administration of chemotherapy after immunotherapy was markedly effective. The two cases included maxillary sinus cancer and laryngeal cancer that were treated with radiotherapy and chemotherapy as first-line treatment. Both cases developed recurrent/metastatic lesion that were treated with anti-PD-1 antibody. However, the lesions increased in size after immunotherapy. Therefore, subsequent chemotherapy with cetuximab and paclitaxel was considered and showed marked reduction of size of the recurrent/metastatic lesions. The two cases suggested that administration of salvage chemotherapy after immunotherapy is promising for recurrent/metastatic head and neck cancer.

Hirosaki Med. J. 70 : 72—76, 2019

Key words: Cancer immunotherapy; Chemotherapy; Anti-PD-1 antibody; Head and neck cancer.

Introduction

Cancer immunotherapy using immune checkpoint inhibitors, such as anti-programmed cell death 1 (PD-1) or anti-programmed cell death-ligand 1 (PD-L1) antibody, has been a hot topic in the field of cancer treatment. In the phase 3 clinical trial CheckMate 141, the anti-PD-1 antibody nivolumab has been shown to improve the overall survival of patients with recurrent/metastatic squamous cell carcinoma (SCC) of the head and neck, compared with the effects of the single-agent therapy of the investigator's choice¹⁾. Nivolumab has recently been approved as a first-line therapy for platinum-resistant recurrent/metastatic head and neck cancer. Platinum resistance is defined as recurrence/metastasis within

less than six months after platinum-based chemotherapy.

When a recurrent/metastatic lesion is not responsive to nivolumab, second-line chemotherapy should be considered. Some studies have reported the influence of anti-PD-1/PD-L1 antibodies on the effects of subsequent salvage chemotherapy in improving the response rates of advanced non-small cell lung cancer (NSCLC)^{2, 3)}. To the best of our knowledge, information on the efficacy of chemotherapy for recurrent/metastatic head and neck cancer after immunotherapy is limited. The present article reports two cases of recurrent/metastatic head and neck cancer, in which administration of chemotherapy after cancer immunotherapy was considerably effective.

Case 1

A 52-year-old man presented to the otorhinolaryngology clinic of a nearby general hospital because of mucoid nasal discharge and right cheek swelling for one month. The patient's past medical history was liver cirrhosis and esophageal varices caused by hepatitis C. An X-ray study demonstrated an abnormal shadow in the right maxillary sinus. Although the doctor who examined the patient initially recommended computed tomography (CT), the patient refused and opted for conservative therapy with carbonylmethyl cysteine and clarithromycin for approximately six months. However, the symptoms did not improve, and the patient lost to follow-up. Two months after the interruption of clinic visits, the patient returned with a complaint of right cheek pain. CT demonstrated a right maxillary sinus that was filled with a mass lesion, accompanied by bone disruption.

The patient was referred to our department for further examination and treatment. Open biopsy proved the lesion to be SCC. Based on the imaging findings of right deep cervical and right submandibular lymphadenopathies, the patient was diagnosed with right maxillary sinus squamous cell carcinoma (T4aN2bM0). Intra-arterial cisplatin with concomitant radiotherapy was administered. The treatment led to a marked reduction in the size of the lesion, which was considered complete remission. Five months after the first chemoradiotherapy, the patient presented with torose lesions on the front area of the ear (Figure 1A). CT demonstrated suspicious metastatic mass lesions in the right parotid gland and lung.

A core needle biopsy of the mass in the right parotid gland revealed lymph node metastasis from SCC, for which treatment with intravenous anti-PD-1 antibody was started. However, after eight courses of anti-PD-1 antibody treatment, the tumor in the right parotid gland increased

in size (Figures 1B and 1C). As a second-line treatment for the metastatic lesion, chemotherapy with a combination of cetuximab and paclitaxel was started. The dose of cetuximab was 400 mg/m² in the first course and 250 mg/m² in the subsequent courses. Paclitaxel was administered in a reduced dose of 60 mg/m² because of thrombocytopenia. With cetuximab and paclitaxel, the metastatic lesions in the right parotid gland began to decrease in size after three courses (Figure 1D) and were nearly diminished after 10 courses of therapy (Figures 1E and 1F). The lung lesions remained stable throughout the course and might have been inflammatory not metastatic. Outpatient chemotherapy with cetuximab and paclitaxel was continued up to the present, and the lesions had been in a stable disease.

Case 2

A 74-year-old man had been monitored in our outpatient clinic for five years after radiotherapy for laryngeal carcinoma. CT, which was performed for medical follow-up, demonstrated an increase in the size of the lymph nodes in the right side of the neck and paraesophageal area. FDG positron emission tomography showed high FDG uptake in the two lymph nodes. Concomitant chemoradiotherapy with intravenous cisplatin resulted in the reduction in the lesion size.

One year after the treatment, CT revealed multiple lung metastases (Figure 2A). Sixteen courses of anti-PD-1 antibody were administered, but the lung lesions increased in size (Figures 2B and 2C). Salvage chemotherapy with cetuximab and paclitaxel was started and continued without severe adverse events until after the eighth course, when the patient presented with respiratory discomfort and malaise. KL-6 increased up to 948 U/mL, and imaging study demonstrated lung interstitial opacities, which were diagnosed as grade 2 interstitial

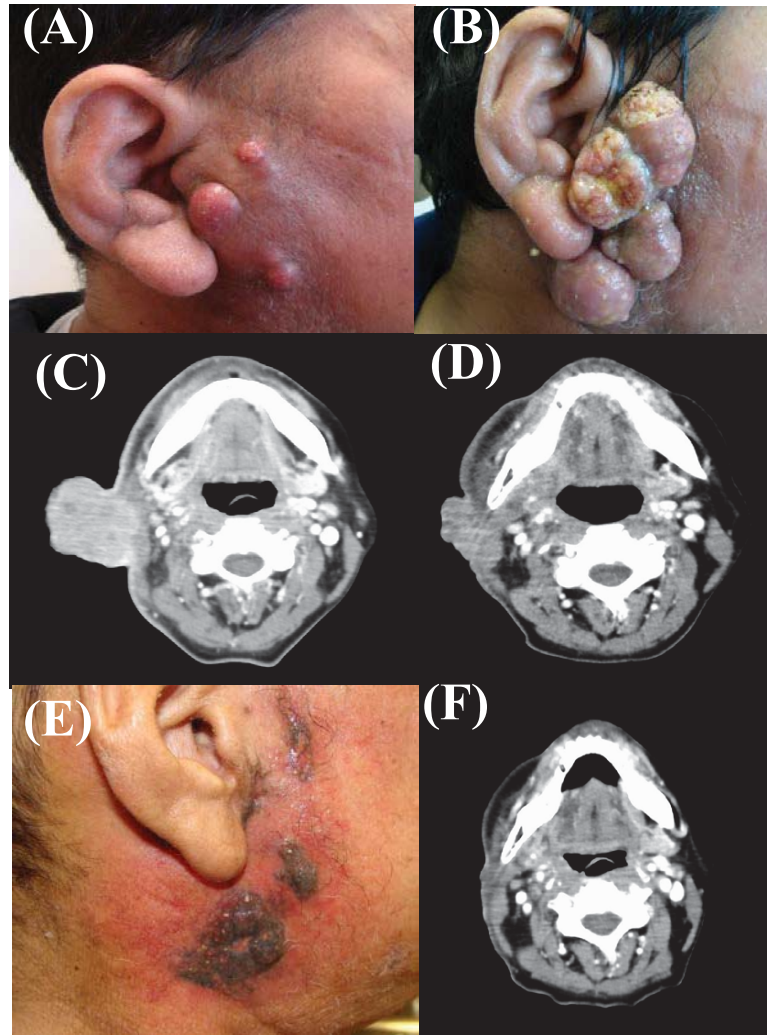


Figure 1 Gross and imaging study findings in Case 1

Gross appearances of (A) locoregional recurrence before immunotherapy and (B) after eight courses of nivolumab are shown. CT shows an (C) increase in the size of the recurrent lesion after nivolumab and (D) decrease in the size after three courses of salvage chemotherapy. (E) Gross appearance after eight courses of chemotherapy and (F) CT findings after 10 courses of chemotherapy are shown.

pneumonia. The patient was hospitalized and administered with systemic steroids and antibiotics, which improved the symptoms and lung opacities. Although the chemotherapy was discontinued, CT revealed remarkable reduction of the metastatic lesions in the lung (Figure 2D).

Discussion

CheckMate 141 reported that the anti-PD-1 antibody nivolumab significantly improved the survival of patients with recurrent/metastatic

head and neck SCC that progressed within six months after platinum-based chemotherapy. Since the approval of anti-PD-1/PD-L1 antibodies for recurrent/metastatic head and neck cancer, there have been an increasing number of cases treated with cancer immunotherapy. However, immunotherapy was shown to be insufficient in some cases, resulting in progression of lesions. In such cases, second- or subsequent-line chemotherapy should be considered. In the two cases presented in this report, the recurrent/metastatic lesion progressed despite administra-

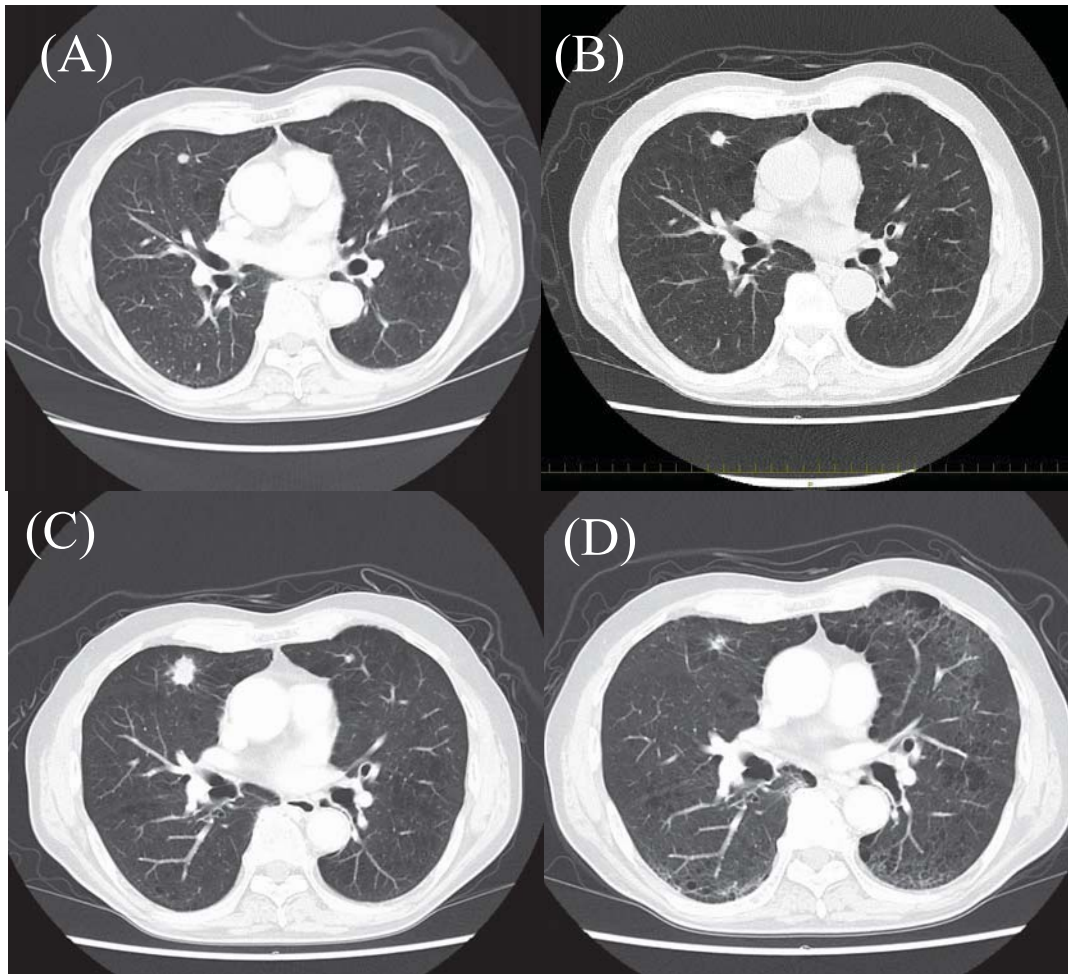


Figure 2 CT imaging findings in Case 2

One year after the treatment to the lymph node metastases, (A) a metastatic lesion in the lung is found and an increase in size after (B) four and (C) 16 courses of nivolumab was observed. (D) After eight courses of chemotherapy, the size of the lung lesion decreased but with the development of interstitial pneumonia.

tion of the PD-1 inhibitor nivolumab but showed significant response to the salvage chemotherapy administered after cancer immunotherapy. Case 1 had been maintained on cetuximab and paclitaxel treatment, without disease progression.

Pseudoprogression is a temporary increase in the total tumor burden and may present with CT imaging findings of increasing nodules, which may indicate T cell infiltration and extensive necrosis. For cases with tumor increase on the first imaging evaluation, the recommendation was to continue immunotherapy and re-evaluate after four weeks when the therapy is con-

sidered beneficial. In case 1, the lesion further increased despite eight courses of cancer immunotherapy; this was considered too long to be regarded as pseudoprogression. Because pseudoprogression was estimated to occur in only less than 1%, expecting it and delaying the chance to switch to an appropriate chemotherapy should be avoided.

Chemotherapy and immunotherapy have been suggested to have a synergistic effect, but the treatment sequence of the two has been controversial. Two clinical studies reported that administration of chemotherapy after first-line cancer immunotherapy improved the overall re-

sponse rate of patients with NSCLC^{2, 3)}. From the viewpoint of basic research, immunotherapy prior to chemotherapy was also supported. In an experiment on mice bearing lung cancer, Fridlender *et al* reported that, compared with chemotherapy alone, a therapeutic sequence of intratumor administration of adenovirus-expressing interferon alpha followed by gemcitabine and cisplatin considerably reduced the tumor⁴⁾. The superiority of immunotherapy followed by chemotherapy may be related to the mechanism of T cell exhaustion. In particular, increased PD-1 expression in CD8+ tumor-infiltrating lymphocytes after long-term chemotherapy leads to T cell dysfunction. Although evaluation of the histologic changes after immunotherapy was not feasible in the two cases reported here, we speculated that prior immunotherapy influenced the cancer microenvironment and led to the remarkable efficacy of the subsequent chemotherapy.

Anti-PD-1/PD-L1 antibodies can be administered to a variety of malignant tumors, such as malignant melanoma, bladder cancer, NSCLC, breast cancer, and thyroid cancer. Therefore, the relevance of the efficacy and histologic type of tumor is unclear. Although the expression of PD-L1, which is a PD-1 ligand that leads to T cell dysfunction, can be a predictor of the efficacy of immunotherapy, the clinical trial CheckMate 141 reported that the benefits of nivolumab are independent of the PD-L1 expression. This argument can be explained through cancer heterogeneity, that is, the expression of PD-L1 can vary from one part to another and can change chronologically.

Conclusion

Administration of chemotherapy after immunotherapy showed remarkable efficacy in the two cases, suggesting that chemotherapy can be a promising choice for cases that do not respond

to immunotherapy with PD-1 inhibitor.

Ethical statement

Publication of the present case report was approved by ethical committee of Hirosaki University.

Conflicts of interest

All authors have no conflicts of interest directly relevant to the content of this article.

Acknowledgment

We would like to give our heartfelt thanks to Professor Matsubara, who offered continuing support and constant encouragement. Special thanks, as well, to Dr. Abe, whose comments made enormous contributions to our work.

References

- 1) Ferris RL, Blumenschein G Jr, Fayette J, Guigay J, Colevas AD, Licitra L, Harrington K, *et al.* Nivolumab for recurrent squamous-cell carcinoma of the head and neck. *N Engl J Med.* 2016;375:1856-67.
- 2) Schvartsman G, Peng SA, Bis G, Lee JJ, Benveniste MFK, Zhang J, Roarty EB, *et al.* Response rates to single-agent chemotherapy after exposure to immune checkpoint inhibitors in advanced non-small cell lung cancer. *Lung Cancer.* 2017;112:90-5.
- 3) Park SE, Lee SH, Ahn JS, Ahn MJ, Park K, Sun JM. Increased response rates to salvage chemotherapy administered after PD-1/PD-L1 inhibitors in patients with non-small cell lung cancer. *J Thorac Oncol.* 2018;13:106-11.
- 4) Fridlender ZG, Sun J, Singhal S, Kapoor V, Cheng G, Suzuki E, Albelda SM. Chemotherapy delivered after viral immunogene therapy augments antitumor efficacy via multiple immune-mediated mechanisms. *Mol Ther.* 2010;18:1947-59.