

CASE STUDY

Comprehensive evaluation including ultrasound monitoring of fetal hemolytic disease in Rhesus E incompatibility

Kasumi Osonoi¹⁾, Ko Kudo¹⁾, Akie Kobayashi¹⁾, Daisuke Matsukura²⁾,
Kanji Tanaka²⁾, Kiminori Terui¹⁾, and Etsuro Ito¹⁾

Abstract: The prediction of the severity of Rhesus E induced-hemolytic anemia is difficult due to low incidence, although ultrasound monitoring of middle cerebral artery peak systolic velocity (MCA-PSV) is useful. We report a case of moderate Rhesus E associated hemolytic disease of newborn even with indicating a high level of MCA-PSV suggesting severe anemia. A 37-year-old multipara woman suspected with severe fetal anemia at 35 weeks of gestation by ultrasound monitoring. However, the fetus showed no findings of hydrops fetalis. A female neonate was born at 38 weeks of gestation by transvaginal delivery without asphyxia. The neonate developed moderate hemolytic disease that was treated with phototherapy, a single dose of human intravenous immunoglobulin and four times of red blood cell transfusions. Exchange transfusion was not needed for treatment. The anti-E antibody of the baby was serially detected which became negative at 6 months of age. A comprehensive evaluation of the fetus for prediction of severity and careful observation for at least six months are crucial in the management of Rhesus E associated hemolytic disease, considering the limitation of ultrasound monitoring of MCA-PSV.

Hirosaki Med. J. 71 : 71—74, 2020

Key words: hemolytic disease; neonates; ultrasound.

Introduction

Hemolytic disease of the fetus and newborn (HDFN), which is caused by maternal antibody-mediated red blood cell destruction, is a rare complication of pregnancy with a frequency of <0.1%.¹⁻⁴⁾ The clinical disease ranges from hyperbilirubinemia to severe hydrops fetalis. The incidence of Rhesus D incompatibility is decreasing because the clinical management is well-established and includes antibody screening and prophylaxis using Rhesus D immunoglobulin treatment.^{1, 3)} In contrast, the clinical assessment and prediction of the severity of Rhesus E induced-hemolytic anemia are not fully understood due to low incidence, although antibody titer and ultrasound monitoring of middle cerebral artery peak systolic velocity (MCA-PSV)

were used to predict fetal anemia.^{1, 5)} We report a case with moderate HDFN that was treated with a single dose of human intravenous immunoglobulin (IVIG) and a cumulative volume of 40 ml/kg of red blood cell transfusion. Exchange transfusion was not needed for treatment.

Case presentation

The mother was a 37-year-old woman of Japanese-descent, gravida 4 para 3, with a history of hypertensive disorders of pregnancy in her first pregnancy. She had no remarkable family history or history of transfusion. The blood group of the mother was A Rhesus-positive. Anti-E antibody was detected at 12 weeks of pregnancy by a screening test, and the anti-E titer was 1:64. At 28 weeks, the anti-E

¹⁾ Department of Pediatrics, Hirosaki University Graduate School of Medicine, Hirosaki, Japan

²⁾ Department of Perinatal Medical Center Hirosaki University Hospital, Hirosaki, Japan

Correspondence: K. Kudo

Received for publication, March 13, 2020

Accepted for publication, April 10, 2020

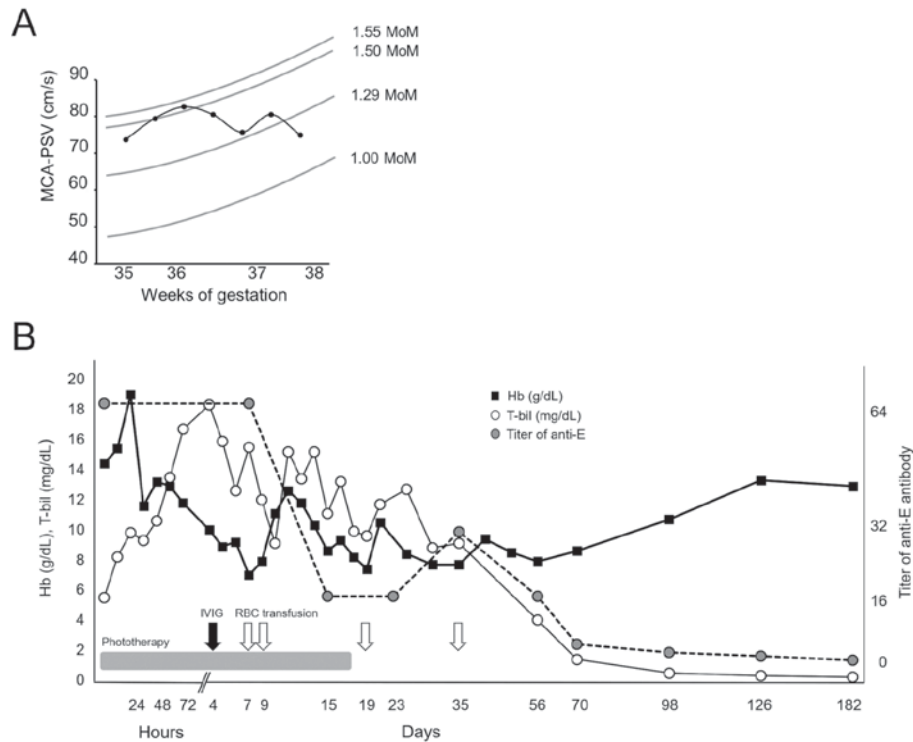


Figure 1 (A) Ultrasound monitoring of middle cerebral artery peak systolic velocity (MCA-PSV) during the pregnancy. The multiple median of MCA-PSV and MCA-PSV value at week 35 to 38 weeks of gestation are shown. MCA-PSV indicated severe anemia at 36 weeks and gradually improved subsequently. Hemoglobin (Hb), total bilirubin (T-bil), intravenous immunoglobulin (IVIG), red blood cell (RBC), middle cerebral artery peak systolic velocity (MCA-PSV), multiples of median (MoM) (B) Timeline of hemoglobin and total bilirubin levels of anti-E antibody-mediated hemolytic anemia of the newborn. Black squares, white circles, and gray circles indicate hemoglobin levels, total bilirubin levels, and titer of anti-E antibody, respectively.

titer was elevated to 1:128, which further increased to 1:256 at 34 weeks. Ultrasound measurement of MCA-PSV indicated 1.50 and 1.55 multiples of median (MoM) at 35 and 36 weeks, respectively. The fetus was suspected to have severe fetal anemia, and the mother was referred to our hospital at 36 weeks of gestation. As shown in Figure 1 A, the MCA-PSV was monitored every week, and the value gradually improved from 1.50 MoM at 37 weeks to 1.00 MoM at 38 weeks, suggesting moderate hemolytic anemia of the fetus.

A female neonate was born at 38 weeks of gestation by transvaginal delivery. The birth weight was 2986 g, and Apgar scores were 8 and 9 at 1 min and 5 min of life, respectively. After birth, the neonate was healthy with mild

jaundice. Laboratory examination of the patient showed the following: complete blood count with hemoglobin, 14.4 g/dL; white blood cell count, $25.5 \times 10^9/L$; platelet count, $461 \times 10^9/L$; red cell mean corpuscular volume, 111 fL; reticulocyte count, 8.9%; albumin, 3.7 g/dL; lactate dehydrogenase, 418 U/L; aspartate aminotransferase, 30 U/L; haptoglobin, 1.0 mg/dL; fibrinogen, 105 mg/dL; and normal prothrombin and active partial thromboplastin time. The initial total serum bilirubin of the patient was 6.0 mg/dL, with 0.8 mg/dL, 5.2 mg/dL, and 0.11 $\mu\text{g/dL}$ of conjugated, unconjugated, and unbound bilirubin, respectively. Peripheral blood smear indicated hemolytic anemia with reticulocytosis and teardrop red blood cells. The blood group of the neonate was O Rhesus-positive, and ccDEe and both

direct and indirect of Coombs' test were positive. The blood group of the father was suspected as heterozygous for antigen because his children showed no history of hemolytic anemia.

A timeline displaying the hemoglobin and bilirubin levels for the neonate is shown in Figure 1 B. Phototherapy was started three hours after birth because of rapid progressive hyperbilirubinemia. The neonate had a peak total bilirubin of 18.3 mg/dL and unbound bilirubin of 1.0 μ g/dL at 93 hours of life and received a dose of IVIG on day 4 and subsequently, transfusions of packed red blood cells (10 ml/kg each) on days 7 and 9. We discontinued the phototherapy on day 18, and bilirubin levels gradually decreased to normal range by 1 month of age. On day 19, the neonate received the third transfusion of packed red blood cells because her hemoglobin dropped to 7.4 g/dL. The baby received a fourth blood transfusion on day 35 due to persistent hemolytic anemia. Eventually, anemia of the infant gradually recovered. The anti-E antibody of the baby was serially detected which became negative at 6 months of age. At 9 months of age, she had no anemia and exhibited normal development.

Discussion

We report a case of moderate Rhesus E associated hemolytic disease even with indicating a high level of MCA-PSV suggesting severe anemia.

The indication criteria of exchange transfusion for Rhesus E associated hemolytic disease is difficult in clinical practice. While most HDFN by Rhesus E incompatibility is not severe, some critical cases develop fetal death.⁶⁾ Therefore, careful observation is critical for the treatment of HDFN with Rhesus E incompatibility due to clinical variations. Previous reports have shown the efficacy of phototherapy and transfusions for

HDFN.⁷⁾ Intravenous immunoglobulin treatment could modulate bilirubin production, the duration of phototherapy, and also reduce the frequency of exchange transfusions, which is effective in severe cases.⁷⁾ However, exchange transfusion is an invasive treatment option because of the risk of complications, such as thrombosis, bleeding and infections.⁸⁾

The MCA-PSV level at 36 weeks of gestation exceeded 1.50 MoM indicating severe fetal anemia considering exchange transfusion. However, we detected no findings of hydrops fetalis, such as fetal subcutaneous edema, fetal pleural effusion and ascites. Based on the findings of fetal well-being, the mother had been carefully observed without termination and we predicted the fetus had mild to moderate anemia despite the high level of MCA-PSV. Although ultrasound monitoring of MCA-PSV is a useful tool for predicting fetal anemia, the value is influenced by several factors. Gestational age affects the sensitivity at a cut-off value of 1.5 MoM is 100%; however the false positive rate increases after 35 weeks of pregnancy.⁵⁾ Other factors include fetal growth restriction, fetal movement, and operator's skill.⁹⁾ It is essential to evaluate fetus condition comprehensively, not by only MCA-PSV measurement.

We also detected re-elevation of anti-E titer on day 35, and anemia persisted for about six months. In general, maternal antibody generally becomes negative by six months after birth, and the half-life of transfused red blood cells is reported to be about 36 days.^{10,11)} A recent study has shown that the transfer of antibodies due to breastfeeding prolonged anti-D antibody-related HDFN.¹²⁾ We speculate that it might be a possible explanation of the re-elevation of anti-E titer because the breastfeeding was started on day13 and suggest that careful observation for at least six months would be needed.

In conclusion, a comprehensive evaluation of the fetus for prediction of severity is crucial in the management of Rhesus E associated hemo-

lytic disease, considering the limitation of ultrasound monitoring of MCA-PSV. All newborns with alloimmunity should be carefully observed for at least six months in case treatment is needed.

Conflict of interest

All authors have no conflicts of interest directly relevant to the content of this article.

Author contributions

K.O., K.K. and E.I. wrote the manuscript. K.O., K.K., A.K., D.M., K. Tanaka, K. Terui and E.I. evaluated the patients, and collected and interpreted the data. All authors read and approved the final manuscript.

References

- 1) Ghesquière L, Garabedian C, Coulon C, Verpillat P, Rakza T, Wibaut B, Delsalle A, et al. Management of red blood cell alloimmunization in pregnancy. *J Gynecol Obstet Hum Reprod.* 2018;47:197-204.
- 2) Moran P, Robson SC, Reid MM. Anti-E in pregnancy. *BJOG.* 2000;107:1436-8.
- 3) Webb J, Delaney M. Red blood cell alloimmunization in the pregnant patient. *Transfus Med Rev.* 2018;32:213-9.
- 4) Yoda M, Hosono S, Nagano N, Yoshikawa K, Takahashi S. Hemolytic disease of the newborn due to anti-E and anti-C antibody following maternal transfusion. *Pediatr Int.* 2017;59:1093-4.
- 5) Mari G, Deter RL, Carpenter RL, Rahman F, Zimmerman R, Moise KJ Jr, Dorman KF, et al. Noninvasive diagnosis by Doppler ultrasonography of fetal anemia due to maternal red-cell alloimmunization. *N Engl J Med.* 2000;342:9-14.
- 6) Chao AS, Chao A, Ho SY, Chang YL, Lien R. Anti-E alloimmunization: a rare cause of severe fetal hemolytic disease resulting in pregnancy loss. *Case Rep Med.* 2009;2009:471623.
- 7) Gottstein R, Cooke RW. Systematic review of intravenous immunoglobulin in haemolytic disease of the newborn. *Arch Dis Child Fetal Neonatal Ed.* 2003;88:F6-10.
- 8) Keenan WJ, Novak KK, Sutherland JM, Bryla DA, Fetterly KL. Morbidity and mortality associated with exchange transfusion. *Pediatrics.* 1985;75:417-21.
- 9) Mari G, Hanif F, Kruger M, Cosmi E, Santolaya-Forgas J, Treadwell MC. Middle cerebral artery peak systolic velocity: a new Doppler parameter in the assessment of growth-restricted fetuses. *Ultrasound Obstet Gynecol.* 2007;29:310-6.
- 10) Maruhashi T, Susa K, Nishimoto N, Sugai T, Yokohama A, Sadakata H, Kouno M, et al. Clinical examination of erythrocyte half-life after exchange transfusion in a newborn with hemolytic disease of the fetus and newborn. *JJTC.* 2012;58:533-8.
- 11) Leuridan E, Hens N, Hutse V, Ieven M, Aerts M, Van Damme P. Early waning of maternal measles antibodies in era of measles elimination: longitudinal study. *BMJ.* 2010;340:c1626.
- 12) Li M, Blaustein JC. Persistent hemolytic disease of the fetus and newborn (HDFN) associated with passive acquisition of anti-D in maternal breast milk. *Transfusion.* 2017;57:2121-4.